



UDC: 615.015.21

DOI: 10.18413/2313-8971-2017-3-2-14-28

Fedosov P.A.¹,
Nikolaevsky V.A.¹,
Chernov Y.N.²,
Buzlama A.V.¹,
Slivkin A.I.¹,
Provotorova S.I.¹

**PRECLINICAL STUDY OF THE EFFICACY AND SAFETY
OF WOUND HEALING GEL CONTAINING CHITOSAN,
TAURINE AND ALLANTOIN**

¹Voronezh State University, 1 University Square, Voronezh, 394018, Russia,

²Voronezh State Medical University named after N.N. Burdenko, 10 Studencheskaya St., Voronezh, 394036, Russia
e-mail: fedosov91@gmail.com.

Abstract

Introduction: The paper deals with the problem of wound healing, which is considered to remain one of the most pressing challenges of the modern medicine, despite a large variety of wound healing preparations. This results from a high level of domestic and military traumatism of the population, and the fact that many registered medications do not meet the requirements for modern wound healing preparations.

Objectives: To develop gel containing chitosan, taurine, allantoin, and to experimentally investigate its wound healing properties in pre-clinical studies on laboratory animals.

Methods: The methodological approach was based on a range of theoretical, pharmacological, toxicological, histological, statistical, physico-chemical, biopharmaceutical, rheological methods, which ensured the development of an optimal, safe and effective wound healing preparation in the gel dosage form.

Results: The developed chitosan gel containing taurine and allantoin meets the major modern requirements for wound and burn care. Physico-chemical compatibility of the chitosan gel components with taurine and allantoin were proved in the experimental studies. When applied either singly or repeatedly on the skin, the developed gel is reported to be of low toxicity; in case of linear wounds, it demonstrates wound-healing properties, ensuring the increase of wound-disruption strength 1.5 times more in comparison with the control; in case of planar full-thickness skin wounds, it provides earlier complete healing (4 days earlier than in the control) and full epithelium recovery in the area of a wound defect. The given gel possesses burn-treating properties exceeding the efficiency of the "Solcoseryl" gel and reducing the half-healing period by 28%. When applied topically, the chitosan gel containing taurine and allantoin reveals anti-inflammatory and capillary-protective properties of moderate degree.

Conclusion: It is possible to use 1.0% chitosan gel with 4.0% taurine and 0.5% allantoin to accelerate healing and provide epithelization without cosmetic defects of conditionally aseptic wounds and thermal skin burns up to IIIa degree to 1% of the body surface area; the gel should be applied 1-3 times a day locally, 0.5 g directly to the wound surface.

Key words: wound healing; gel; preclinical studies; wound healing gel; chitosan; taurine; allantoin.

Introduction

The treatment and care of wounds of various etiology are stated to remain an acute issue of current medicine, since the level of military, domestic, sports and industrial traumatism is

increasing, and annually one in ten inhabitants of Russia receives injuries of various severity [1, 2]. Currently over 1000 pharmaceuticals are registered as preparations for topical wound healing on the territory of the Russian Federation; however, not

all of them meet the requirements for adequate wound healing preparations [3, 4].

Use of combined topical preparations revealing synergism of active agents and bases in various dosage forms – aerosols, ointments, pastes, gels, liniments and solutions – is considered to be more preferable. According to the recent scientific research data gels are reported to be the preparation of choice for wound and burn care, since they have a number of advantages in comparison with other dosage forms, i.e., they do not disrupt fluid balance and gas exchange; their pH ranges from 4.0 to 6.0, which is close to that of the skin surface; they are easily applied and smoothly spread over the skin surface; they are able to bind exudates and prevent reverse migration of microorganisms into a wound; they have cooling effect as a result of water evaporation; they contribute to processes of granulation and epithelization; they are able to successfully release active agents out of the base, provide deep penetration in tissues, increase prolonged effect of active agents and are effective for 18-24 hours [5, 6]. Natural biopolymers such as chitosan extracted from crustacean shells are of special attention among the great variety of gel bases, since they maintain humid conditions and gas exchange in a wound. Besides, they provide the development of the acidic environment contributing to reparative processes, and have an antibacterial and antioxidant effect [7, 8, 9]. The choice of components was performed on the basis of the data obtained experimentally in certain preclinical studies. Taurine (2-aminoethanesulfonic acid) was stated to be a promising agent for wound healing as the substance having an anti-oxidant, anti-inflammatory, angioprotective, membrane-stabilizing, osmoregulatory effect. Its topical application increased the wound-disruption strength, and reduced malondialdehyde and histamine level in the wound tissue [10, 11]. Allantoin was also considered to be one of the highest potential agents; this component is noted to be a low molecular heterocyclic compound having

a wound healing effect due to stimulation of fibroblast proliferation and synthesis of extracellular matrix; this leads to the formation of a negligible scar [12, 13, 14, 15, 16].

Thus, the development of a balanced and effective wound healing preparation for the external use in the form of gel containing chitosan, taurine and allantoin is considered to be a currently important line of research nowadays; this gel should exceed existing analogues and meets the majority of modern requirements towards wound healing preparations that eventually allows extending the range of these products on the Russian pharmaceutical market.

All the above mentioned helps define the aim of this research study: to develop gel containing chitosan, taurine, allantoin and experimentally investigate its wound healing properties in pre-clinical species.

Materials and methods

The study was conducted in accordance with The Guidelines on Pre-Clinical Trials of Pharmaceuticals, Part I (Mironov A.N., 2012). It was performed on the basis of the Pharmaceutical Faculty of the Federal State-Funded Educational Institution of Higher Education “Voronezh State University”. Male and female conventional, sexually mature, white outbred mice, rats and Guinea pigs were included in the study. The methodological approach was based on a range of theoretical, pharmacological, toxicological, histological, statistical, physico-chemical, biopharmaceutical, rheological methods, which ensured the development of an optimal, safe and effective wound healing preparation in the gel dosage form.

The research design followed the rules and regulations of the Ethical Principles and Guidelines for Experiments on Animals, was conducted in accordance with the requirements of the European Convention for the Protection of Vertebrate Animals used for Experimental and other Scientific Purposes (Guidelines for accommodation and care of animals); it fully reflects the thesis structure (Fig. 1).

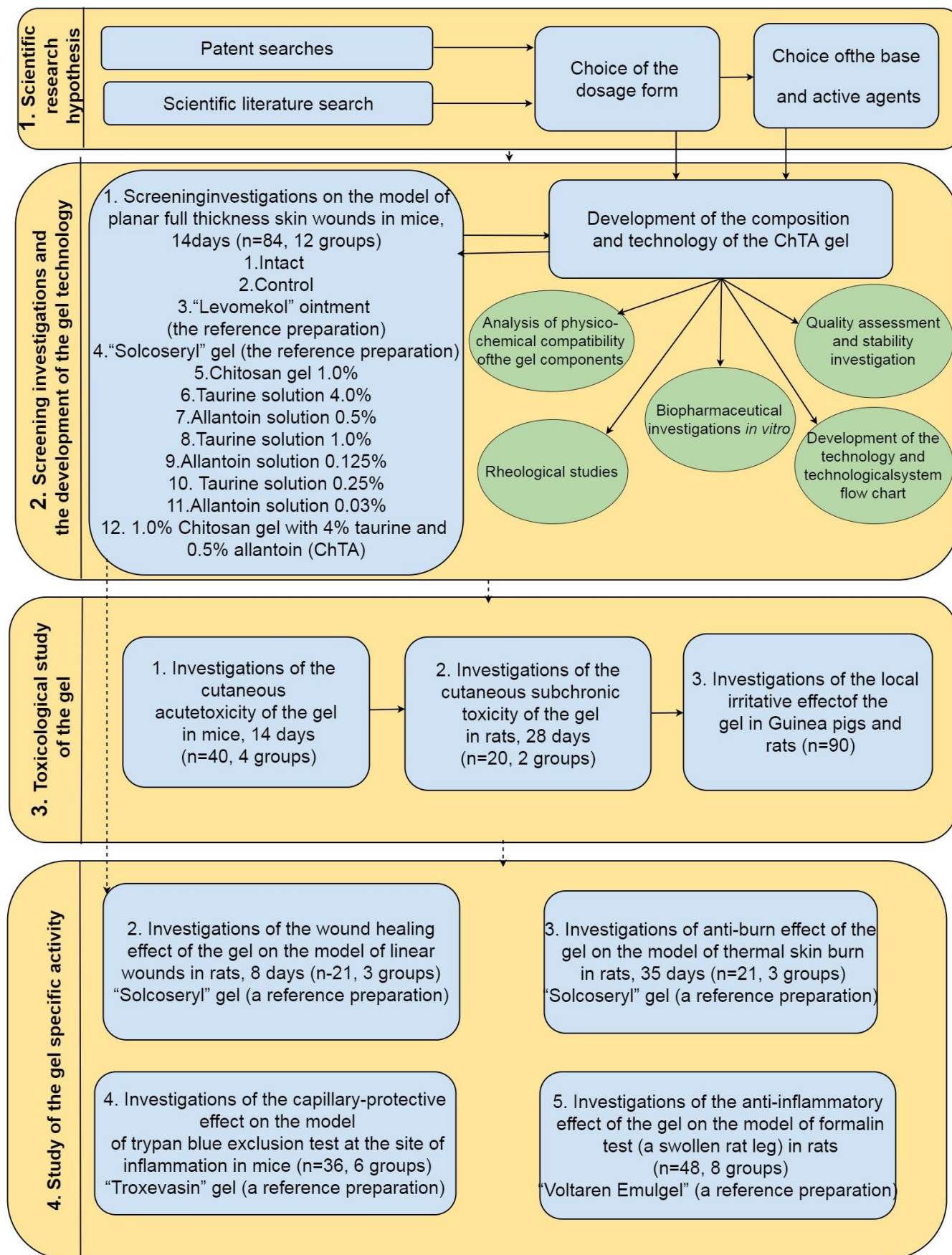


Fig. 1. The research design

381 pre-clinical species were included in the study: 160 3-month-old conventional, sexually mature, white outbred mice (females and males) weighed 18-25 g; 176 3-month-old conventional, sexually mature, white outbred rats (females and males) weighed 180-220 g and 5-month-old conventional, sexually mature, white outbred rats (females and males) weighed 280-300 g; 45 2-month-old white color Guinea pigs (females and males) weighed 350-400 g. The animals were taken from the vivarium of the Federal State Budget Educational Institution of Higher Education "Voronezh N.N.Burdenko State Medical University". The animals were kept in the vivarium of the Federal State-Funded Educational Institution of Higher Education "Voronezh State University" in accordance with the sanitary rules and standards; they received full-value granulated meal (AO "Voronezh Experimental Feed Plant", Russia) with free access to water; the cleaning of cages was carried out daily.

The plan and the study protocol were approved by the Ethical Committee on the Expertise of Biomedical Research of the Federal State-Funded Educational Institution of Higher Education "Voronezh State University" (Protocol No. 42-02, adopted on 05.10.2015). The study was performed in accordance with the requirements of the European Convention for the Protection of Vertebrate Animals used for Experimental and other Scientific Purposes (1986); the Principles of Good Laboratory Practice GOST R-53434-2009; and the Order of the Ministry of Health and Social Development of the Russian Federation, August 23, 2010, No. 708n "About the approval of laboratory practice rules".

The target of research was the chitosan gel with taurine and allantoin (ChTA) developed under supervision of Doctor of Pharmacy, Professor Slivkin A. I. at the Department of Pharmaceutical Chemistry and Pharmaceutical Technology of the Pharmaceutical Faculty of the Federal State-Funded Educational Institution of Higher Education "Voronezh State University" [17].

The composition of the gel is developed on the basis of pharmacological and technological data obtained during the study. The substances used in the study are as follows: Chitosan (2-amino-2-deoxy-(1→4)-β-D-glucan) of high viscosity, extracted from crab shells, produced in Sigma-Aldrich, Japan, the United States Pharmacopeia (USP 34 NF 29), with weight-average molecular weight equal 600 kDa and the degree of deacetylation equal 85%; Taurine (2-aminoethanesulfonic acid) 99%, ZAO "Vekton", Russia, Pharmacopeian Monograph.2.1.0039.15;

Allantoin (5-ureidohydantoin) 98%, Acros Organics, Belgium, the United States Pharmacopeia (USP 34 NF29).

The development of the chitosan gel containing taurine and allantoin was based on physico-chemical, pharmacological, rheological and biopharmaceutical investigations.

Cutaneous acute toxicity was investigated under the application use of the gel in male and female mice (n=40, 21,1±2, 3 g) in accordance with The Guidelines on Pre-Clinical Trials of Pharmaceuticals, Part I (Mironov A.N., 2012); the gel was applied eight times during 24 hours with one-hour break between applications. The study of cutaneous sub-chronic toxicity was conducted in accordance with the requirements of "the Guidelines for the Testing of Chemicals. Repeated Dose Dermal Toxicity: 21/28-day Study", GOST 32642-2014 (2015). Cutaneous sub-chronic toxicity was studied under the application use of the gel in male and female rats (n=20, 206, 8±12.1 g). Local irritative effect of the ChTA gel was investigated using the technique of cutaneous applications in male and female white color Guinea pigs (n=20, 363,7±13,9 g) divided into two groups, 10 species in each group. The conjunctival provocation test was performed in male rats (n=25, 288, 4±6.8 g) and male and female white color Guinea pigs (n=25, 355, 4±19, 7). The tube test was used to evaluate the ChTA gel absorption through skin in male rats (n=20, 215, 7±8.9 g).

The impact of the ChTA gel and each of its components and reference preparations – the "Solcoseryl" gel and the "Levomekol" ointment – on the healing dynamics were studied on the model of planar full-thickness skin wounds in male mice (n=84, of 20.0±1.5 g).

Investigations on the model of linear wounds were performed in male rats (n=21, 203, 4±12.0 g). Euthanasia was conducted on the 8th day by overdosing of ether anesthesia; 2×3 cm flap was incised from the wound surface; a tensiometer was used to measure the wound-disruption strength [18].

Anti-burn effect was studied on the model of thermal skin burn in male rats (n=42, 276, 0±17.6 g). Experimental burn wounds were simulated using an electrical device for the contact thermal burn. The metal plate of the device, sized 2.5×2.5 cm, heated to 200 °C was applied to the skin for 10 seconds; this resulted in the third-degree burn as big as 600±50 mm².

Trypan blue exclusion test at the site of inflammation was used to evaluate a capillary protective effect of the gel in male mice (n=36, of 18.8±2.0 g). Formalin test was used to investigate topical anti-inflammatory effect in male rats (n=48, 280, 0 ± 20.0 g) (a swollen rat leg).

Pathological, hematological and biochemical investigations were carried out according to conventional methods (Malakhova M. Y., 1995; Kishkun A. A., 2007 Suleymanov S. M., 2012). Statistical significance of findings obtained in the intact, control and experimental groups was assessed by Student's t-test in case of parametric distribution, and Wilcoxon-Mann-Whitney test in case of non-parametric distribution.

Results

When developing pharmaceuticals with complex compositions a special attention is paid to the study of physico-chemical compatibility. Compatibility of the components of the chitosan gel with taurine and allantoin was assessed and analyzed by the method of infrared spectroscopy. The obtained infrared specters of taurine, allantoin and chitosan substances are given in Figure 2.

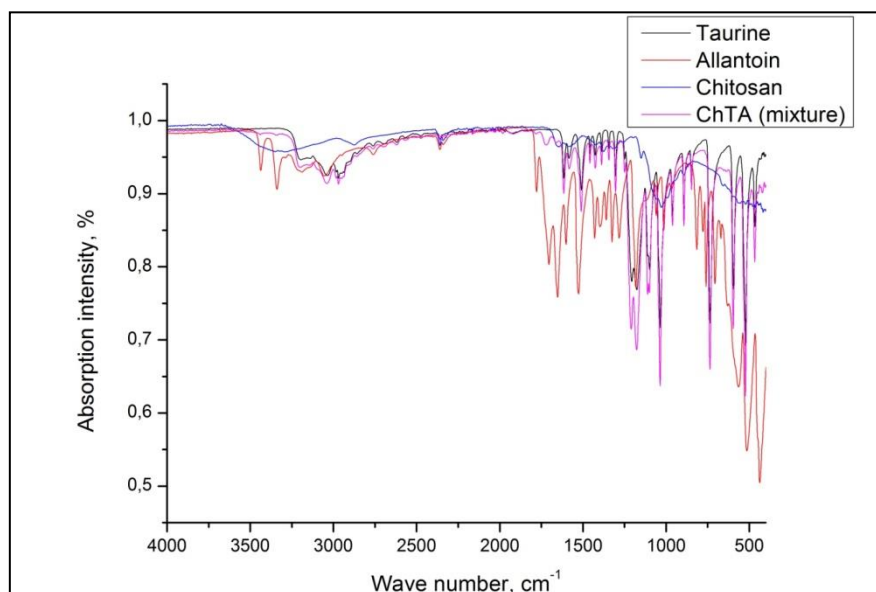


Fig. 2. Infrared specters of taurine, allantoin, chitosan and their mixture

The analysis of infrared specters of the chitosan, taurine and allantoin mixture has proved that specific absorption bands responding to sulfonic stretching vibrations in the molecules of taurine, amides stretching vibrations in the molecule of allantoin, amines stretching vibrations in the molecule of chitosan are retained. Moreover, there have not been revealed new absorption bands in the mixture; this fact indicates the lack of covalent binding of allantoin and taurine molecules with chitosan macro-molecules. The data obtained support the absence of physico-chemical interrelations between the gel components and give an opportunity to combine them when developing a pharmaceutical preparation.

Concentration of the gel-forming agent was chosen under the visual inspection of the created model samples with concentrations of 0.5%, 1.0%, 2.0%, 3.0%; the following indicators were taken into account: swelling property, transparency, homogeneity, spreading capacity of the gel. Optimal

concentration of the chitosan gel-forming agent equal 1.0% was used in further studies. Rheological investigations of the ChTA gel model samples were conducted to study the shear stress at temperatures 20°C and 37°C. It has been established that the structural viscosity of the ChTA gel slightly decreased at the temperature 37 °C, however, it remained within the range of the rheological optimum for the gels (from 2 to 10 Pa·s). Ascending and descending curves of hysteric loops shown in Figure 3 indicate that the studied ChTA gel has the thixotropic properties; this fact predicts its optimal flow property during mixing, which is necessary to facilitate packaging of the preparation due to its ability to be easily squeezed out of a tube and conveniently applied on the skin. Biopharmaceutical investigations support the fact that the active agents of the given composition of the gel are equally released during 24 hours (Figure 4).

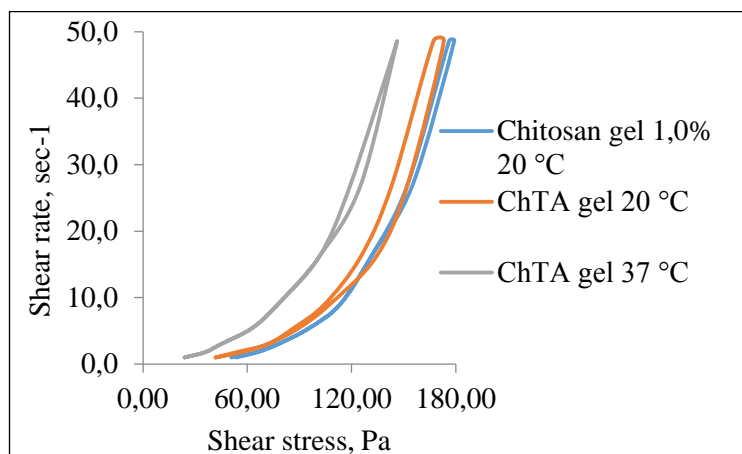


Fig. 3. Rheograms of the gel flows

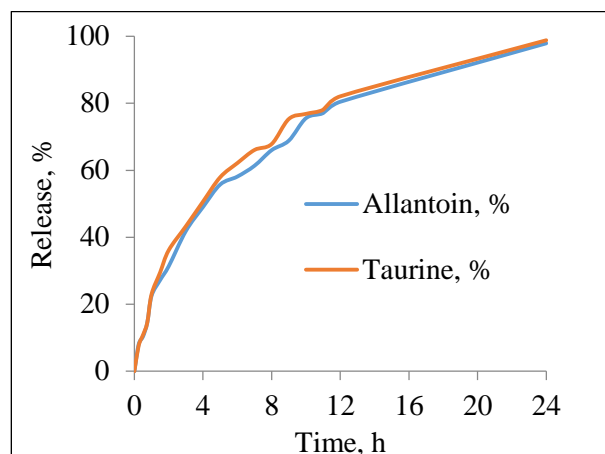


Fig. 4. Dynamics of taurine and allantoin release

The following composition of the gel has been developed on the basis of the data obtained in the study of the compatibility of the components, rheological characteristics, in the biopharmaceutical, screening and pharmacological investigations:

Chitosan	1.0 g
Taurine	4.0 g
Allantoin	0.5 g.
Acetic acid	0.5 g.
Purified water	up to 100 g.

Quality standards of the chitosan gel with taurine and allantoin have been defined taking into account the following parameters: description, identification, assay, pH, microbial purity, container fill and viscosity. The shelf-life of the chitosan gel with taurine and allantoin has been stated to be 18 months at the temperature 2- 8°C.

When investigating the acute toxicity of the ChTA gel LD₅₀ was calculated on the Berens formula; the Gaddam formula was used to assess the value of standard error. When applying the ChTA gel on the skin LD₅₀ constituted 719.58±99.10 g/kg; this exceeded an assumed therapeutic dose equal 0.2 – 0.5 g/kg in 3600 times and proved the high level of safety and low risk of overdosing. Therefore, the chitosan gel with taurine and allantoin is stated to be low toxic and may be included in the IV substance hazard category – low-hazardous substances (Berezovskaya I.V., 2003; GOST 12.1.007-76).

No skin-resorptive, locally irritative or organotropic effects have been registered when applied the ChTA gel daily for 28 days, dosed 7.2 g/kg that corresponds to 1/100 of LD₅₀. Histological investigations proved that no alterations were observed in the structural organization of the liver, kidneys and skin of white rats after repeated

application of the ChTA gel during 28 days in comparison with the control group.

Application of the ChTA gel on the conjunctiva of Guinea pigs and rats was accompanied with short-term slight redness disappearing in 5 minutes; no irritative effect was observed in 15 minutes or 24 hours. This slightly expressed irritative effect likely resulted from the occurrence of 0.5% acetic acid. In general the ChTA gel does not have irritative effect on the conjunctiva.

The comparative evaluation of the influence of the chitosan gel with taurine and allantoin on the dynamics of the healing process performed on the planar full thickness wounds in mice proved that animals favourably tolerated application of the chitosan gel with taurine and allantoin; the gel did not result in the irritative effect, hyperemia or swelling of the skin surfaces; it did not influence the level of general moving activity of pre-clinical species. No fatal cases, wound abscess or complicated course of the wound process were registered during the period of observation; the gel was easily applied on the wounds, absorbed wound discharges, did not desiccate a wound bed and kept the humid environment in a wound.

Gradual decrease of the wound area was observed at all stages of the wound process during the whole research period. In the third group the application of the “Levomekol” ointment reduced the wound area by 16.38% on the 9th day in comparison with the control (p<0,05). In the fourth group the use of the “Solcoseryl” gel resulted in the reduction of the wound healing period by 2 days; the gel reliably had a positive impact on the reduction of the wound area by 29,93% on the 7th day in comparison to the control (p<0,05). In the fifth group the wounds were treated with the 1.0% chitosan gel, which caused the

reduction of the wound healing period by 3 days; on the 6th and 8th day the wound area decreased by 22.81% and 40.51% respectively in comparison to the control ($p < 0.05$). In the sixth group the wound area reduced after the application of the 4.0% taurine solution on the wound surface by 21.07% and 35.75% on the 5 and 8 day respectively in comparison with the control ($p < 0.05$). In the seventh group the 0.5% allantoin solution was applied on the wound surface of animals; on the 7th day this resulted in the accelerated wound healing by 25.38% ($p < 0.05$). In the eighth group, where the wounds were treated with the 1.0% taurine solution, there was noted the reduction of the wound area by 19.88% on the 8th day, by 20.27% on the 9th day in comparison with the control ($p < 0.05$). In the ninth group the wounds were irrigated with the 0.125% allantoin solution that led to the reduction of the wound area by 11.89% on the 7th day in comparison with the control ($p < 0.05$). In the tenth group the wounds were irrigated with the 0.25% taurine solution, in the eleventh group the 0.03% allantoin solution was applied; slight improvement of the wound healing by 8.20% and 6.03% respectively were registered on the 7th day in comparison with the control. In the twelfth group the treatment of the wound surface with the developed ChTA gel contributed to the full wound recovery 4 days earlier in comparison with the

control group; the wound-healing effect became apparent right at the end of the 1st day and was characterized by the decrease of the wound area by 5.62%, on the 7th day the wound area decreased by 42.60%, on the 9th day the wound area decreased by 56.62% in comparison with the control ($p < 0.05$). The ChTA gel reduced the time of the wound healing by 4 days when compared with the “Levomekol” ointment and decreased the wound area by 40.24% on the 9th day ($p < 0.05$); the treatment of the wound surface with the ChTA gel accelerated the process of wound healing by 25.38% on the 9th day ($p < 0.05$) when compared with the “Solcoseryl” gel; the data obtained are presented in Table 1.

Half-healing periods were determined based on the dynamics of alteration of the wound area in the control and experimental animals. The data obtained are given in Figure 5.

Application of the combined ChTA gel reduces the time of wound half-healing by 47.94% ($p < 0.05$) when compared to untreated animals. Comparative analysis of the wound healing efficiency of the ChTA gel proves that it reduces the period of wound half-healing in comparison with the chitosan gel by 23.95%, in comparison with the “Solcoseryl” gel by 17.35%, in comparison with the “Levomekol” ointment by 38.71% ($p < 0.05$).

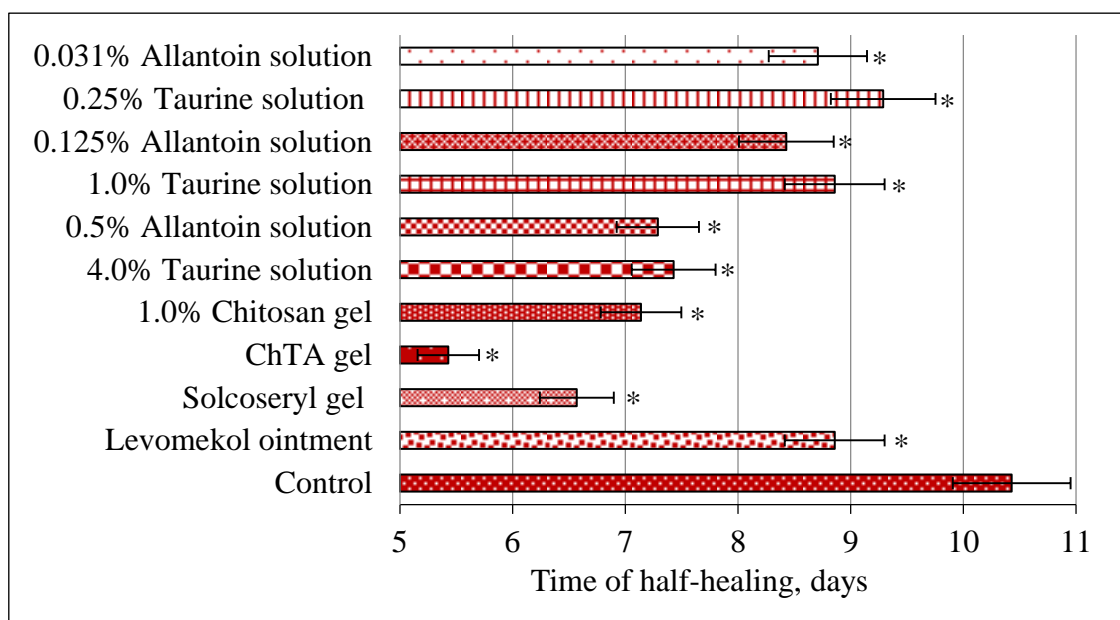


Fig. 5. Half-healing period of planar experimental wounds.

Note: * – $P < 0.05$ – statistical significance in comparison with the control

Table 1

Comparative evaluation of the wound-healing activity of the chitosan gel with taurine and allantoin and its components, “Solcoseryl” gel, “Levomekol” ointment on the model of planar full-thickness wound

Day	Area of planar full-thickness wound, mm ²										
	Control	Levomekol Ointment	Solcoseryl gel	1.0% Chitosan gel	ChTA gel	Taurine solution 4,0%	Allantoin solution 0,5%	Taurine solution 1,0%	Allantoin solution 0,125%	Taurine solution 0,25%	Allantoin solution 0,031%
0	0.65±0.03	0.62±0.03	0.66±0.04	0.63±0.05	0.61±0.04	0.63±0.06	0.64±0	0.63±0.05	0.63±0.04	0.64±0.06	0.62±0.05
1	0.58±0.07	0.57±0.05	0.62±0.07	0.58±0.08	0.51±0.02 ^{**•}	0.57±0.07	0.56±0.02	0.65±0.05 ⁺⁺	0.63±0.03 ⁺	0.61±0.04	0.60±0.05
2	0.58±0.07	0.58±0.04	0.61±0.07	0.56±0.08	0.48±0.03 ^{**+•}	0.55±0.05	0.56±0.05	0.63±0.05 ⁺⁺	0.62±0.03 ⁺⁺	0.59±0.03	0.57±0.05
3	0.56±0.07	0.54±0.06	0.53±0.08	0.48±0.03 ^{**}	0.44±0.03 ^{**+}	0.49±0.07	0.50±0.06	0.62±0.03 ⁺	0.59±0.05 ⁺⁺	0.57±0.00	0.56±0.05
4	0.57±0.05	0.54±0.07	0.51±0.04	0.43±0.05 [*]	0.36±0.03 ^{**•}	0.46±0.04 [*]	0.45±0.04 [*]	0.56±0.05 ⁺	0.55±0.05 ⁺	0.54±0.03	0.53±0.03
5	0.56±0.05	0.54±0.07	0.47±0.05 [*]	0.36±0.04 [*]	0.30±0.03 ^{**•}	0.41±0.03 [*]	0.40±0.03 [*]	0.52±0.03 ⁺	0.53±0.03 ⁺	0.51±0.02 ^{**}	0.53±0.03
6	0.53±0.07	0.52±0.06	0.37±0.06 [*]	0.37±0.04 [*]	0.25±0.03 ^{**•}	0.35±0.03 [*]	0.33±0.04 [*]	0.49±0.05 ⁺	0.47±0.03 ⁺	0.47±0.03 ^{**}	0.47±0.03 ^{**}
7	0.49±0.07	0.47±0.06	0.30±0.07 [*]	0.33±0.03 [*]	0.20±0.04 ^{**•}	0.33±0.02 [*]	0.32±0.05 [*]	0.42±0.03 ^{**+}	0.40±0.02 ^{**+}	0.43±0.04	0.43±0.04
8	0.48±0.07	0.43±0.05	0.27±0.08 [*]	0.21±0.06 [*]	0.11±0.08 ^{**+•}	0.24±0.05 [*]	0.22±0.02 [*]	0.34±0.03 ^{**+}	0.30±0.03 ^{**+}	0.38±0.02 [*]	0.37±0.04 [*]
9	0.40±0.06	0.28±0.08 ^{**}	0.20±0.08 [*]	0.16±0.08 [*]	0.03±0.02 ^{**+•}	0.14±0.07 [*]	0.15±0.04 [*]	0.26±0.03 ^{**+}	0.23±0.04 ^{**+}	0.33±0.03 ^{**}	0.30±0.04 [*]
10	0.34±0.07	0.21±0.04 [*]	0.09±0.04 [*]	0.10±0.05 [*]	0.01±0.01 ^{**•}	0.1±0.05 [*]	0.07±0.02 [*]	0.16±0.03 ^{**+}	0.09±0.02 [*]	0.25±0.02 [*]	0.18±0.02 [*]
11	0.26±0.04	0.17±0.04 [*]	0.06±0.06 [*]	0.02±0.01 [*]	0	0.07±0.05 [*]	0.02±0.02 [*]	0.09±0.03 [*]	0.02±0.01 [*]	0.19±0.03 [*]	0.08±0.01 [*]
12	0.14±0.06	0.07±0.05 ^{**}	0.02±0.01 [*]	0	0	0.05±0.04 [*]	0.01±0.01 [*]	0.04±0.02 [*]	0.02±0.01 [*]	0.08±0.01 ^{**}	0.03±0.01 [*]
13	0.09±0.07	0.03±0.04	0	0	0	0	0	0.01±0.01	0.01±0.01	0.02±0.01	0.01±0.01
14	0.09±0.07	0.01±0.02	0	0	0	0	0	0	0	0	0

Note: * – P<0.05; ** – P<0.01 – statistical significance in comparison with the control; + – P<0.05; ++ – P<0.01 – statistical significance in comparison with the 1.0% chitosan gel ; • – P<0.05; ● – P<0.01 – statistical significance in comparison with the “ Solcoseryl” gel.

At all stages of the wound process the maximal effect was notably manifested in the ChTA group, wherein, the small scar was formed on the 14th day of

the experiment. There were conducted morphometric investigations of planar full-thickness skin wounds (Table 2).

Table 2

Morphometric parameters of planar full-thickness wounds

Group of animals	Transverse size of epithelium, mm ²	Number of cellular elements of a skin scar, inc. × 400.
Intact	66.98±4.48	-
Control	21.83±2.68*	169.60±9.00
Levomekol ointment	24.76±3.63*•	105.60±4.81•
Solcoseryl gel	34.72±4.07*•	74.43±6.20•
ChTA gel	42.58±3.69*•	40.10±5.08•
1,0% chitosan gel	27.55±2.83*•	84.27±6.49•
Taurine solution 4,0%	25.09±2.67*•	83.97±3.67•
Allantoin solution 0,5%	24.59±3.11*•	86.03±5.51•

Note: * – P<0.05 – statistical significance in comparison with the intact group; • – P<0.05 – statistical significance in comparison with the control.

In the group of animals where the wound surface was treated by the ChTA gel the epithelium of the wound defect area was completely recovered. Proliferation of the epithelium and the introduction of the basement membrane in the underlying tissue was revealed, fibrous connective tissue completely filling the volume of the wound defect was formed. Thick layer including hyalinized, collagen-rich connective tissue was formed under the epithelium. It should be noted that scar tissue loosening and decrease of vessels amount were observed with that (Figure 6C).

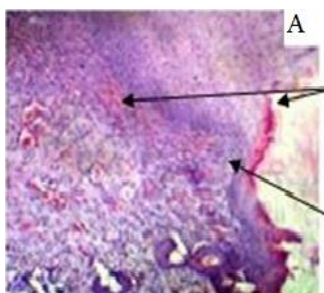


Fig. 6A. A histological picture of the epidermis of the skin of the control group mice.

Note: staining of hematoxylin-eosin. inc. × 200. Cells of all layers of the skin have multidirectional sizes and shapes, papillary dermis layer is smoothed

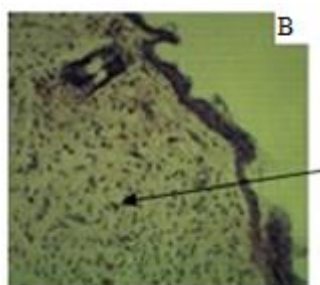


Fig. 6B. A histological picture of the epidermis of the skin of mice after the action of the gel "Solcoseryl".

Note: staining of hematoxylin-eosin. inc. × 200. There is no exudation and edema

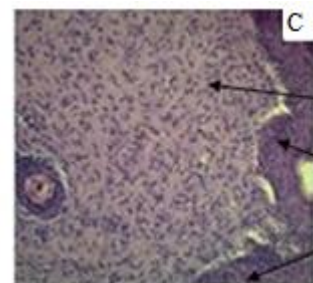


Fig. 6C. A histological picture of the epidermis of the skin of mice after exposure to the chitosan gel with taurine and allantoin.

Note: staining of hematoxylin-eosin. inc. × 200. Fibroblasts and fibrocytes predominate over other types of cells, complete restoration of the epidermis is observed, collagen fibers have formed beams of various thicknesses and directions

Thus, it has been established that on the model of the planar full-thickness wound the ChTA gel provides complete wound healing 4 days earlier than in the control group significantly exceeding the "Levomekol" ointment and the "Solcoseryl" gel by its efficiency; it ensures the reduction of the wound area by 40.24% and 25.38% respectively on the 9th day, provides complete epithelium restoration of the wound defect area due to reduction of proliferative inflammatory processes and complete scar involution.

Comparative evaluation of the wound healing action of the chitosan gel with taurine and allantoin on the model of the linear wounds in rats demonstrated that the wound-disruption strength value constituted 68.36±2,04 g/mm² on the 8th day after the injury in the control group. The results of wound-tensiometric investigations of linear wounds are shown in Figure 7. Application of the "Solcoseryl" gel on the 8th day significantly increased the wound-disruption strength by 14.6% in

comparison with the control ($p < 0.05$) and constituted $78.36 \pm 2.17 \text{ g/mm}^2$. The ChTA gel provided increase of the wound-disruption strength by 50.4% as compared to the control ($p < 0.05$) and constituted

$102.79 \pm 2.75 \text{ g/mm}^2$. The ChTA gel in comparison with the “Solcoseryl” gel increased the strength of wound healing by 31.2% on the 8th day ($p < 0.05$).

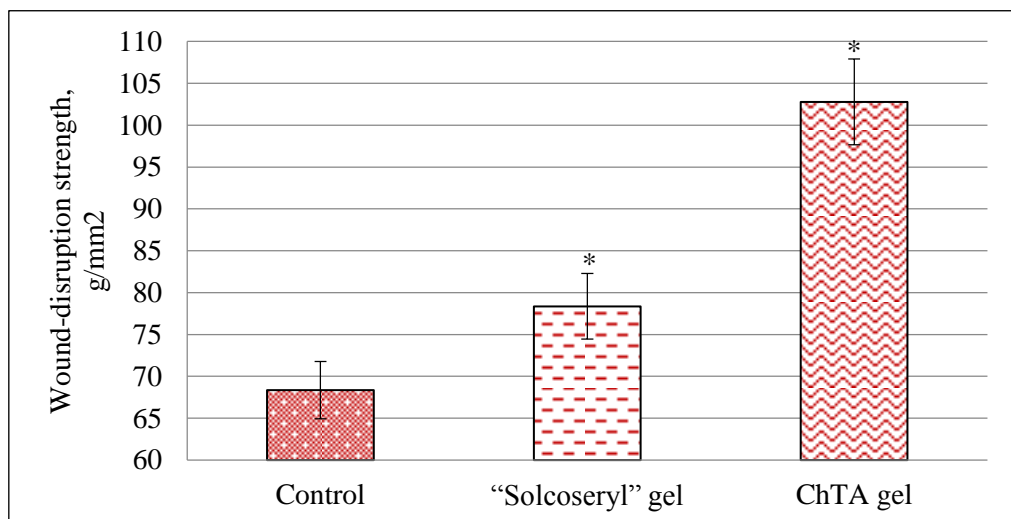


Fig. 7. Wound-tensiometric findings of the linear skin wound.

Note: * – $P < 0.05$ – statistical significance in comparison with the control;

• – $P < 0.05$ – statistical significance in comparison with the reference preparation

On the 8th day application of the ChTA gel resulted in the increased amount of lymphocytes by 3.14% ($p < 0.01$), decreased amount of young, segmented, and stab neutrophils by 0.43%, 1.29%, and 1.86% respectively ($p < 0.05$) in comparison with the control; with that, the shear index constituted 0.09 that indicated at the ChTA gel ability to reduce the severity of the inflammatory process. In general, during the experiment the level of total protein in blood serum in all groups was within the limits of species-specific norms for rats. On the background of the ChTA gel application on the 3th and 8th day there was stated the reduced level of the substances of low and average molecular weight by 38.8% and 37.0% respectively in comparison with the

control ($p < 0.05$) and by 28.9% and 12.2% in comparison with the “Solcoseryl” gel group ($p < 0.05$); this supports the decrease of non-specific signs of inflammation and intoxication.

Evaluation of the anti-burn effect of the chitosan gel with taurine and allantoin on the model of thermal skin burn allowed to conclude that the application of the ChTA gel in comparison with the “Solcoseryl” gel accelerated the process of burn wound healing by 13.85% and 25.42% on the 10th and 25th day respectively ($p < 0.05$) and provided the complete burn wound healing 5 day earlier than in the control group (Table 3).

Table 3

Comparative evaluation of wound-healing activity of the chitosan gel with taurine and allantoin, the “Solcoseryl” gel on the model of a linear skin wound

Day	Burn wound area, mm ²		
	Control	Solcoseryl	ChTA
0	562.29±29.19	569.00±27.18	580.14±15.93
1	580.43±26.78	586.07±16.90	608.21±23.53
5	595.93±32.35	593.93±17.53	536.29±14.82*•
10	517.29±31.67	437.64±19.51*	365.86±32.12*•
14	449.71±14.33	377.00±13.71*	295.57±34.20*•
20	342.86±23.59	286.29±20.24*	179.00±26.86*•
25	297.29±29.76	235.86±16.49*	93.00±22.57*•
28	247.71±28.45	117.57±33.39*	34.43±4.65*•
30	138.57±5.63	49.57±10.20	0
35	3.71±4.24	0	0

Note: * – $P < 0.05$ – reliability of the differences in comparison with the control; • – $P < 0.05$ – reliability of the differences in comparison with comparison drug.

Application of the ChTA gel reduced the time of wound half-healing by 44.74% ($p < 0.05$) in comparison with the control group that constituted 14.29 ± 2.93 days. The comparative analysis of the wound-healing efficiency of the ChTA gel stated that the gel contributed to the reduction of the half-healing period of burn wounds by 28.55% in comparison with the "Solcoseryl" gel. Treatment of burn wounds using the ChTA gel resulted in formation of a negligible post-burn scar. Histological tests of the skin of white rats performed on the 28th day demonstrated that the gel application caused intensification of regenerative processes in the wound defect. In the epidermis the maturity of granular, thorny, and basal layers in the absence of inflammatory infiltrate was clearly recognized. In the dermis lympho-histiocytic infiltrate was absent. In the granulation tissue the fibrous structures prevailed; this is considered to be the criterion of maturity (Figure 8C).

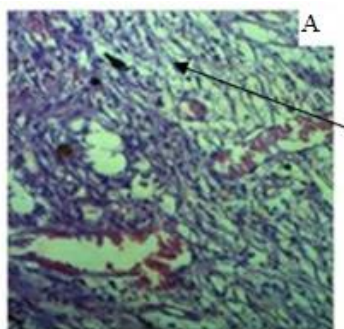


Fig. 8A. Histological picture of the epidermis of the skin of the control group rats
Note: staining of hematoxylin-eosin. inc. $\times 160$.
There is a network of "young" fibroblasts

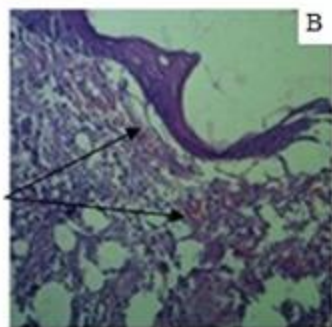


Fig. 8B. A histological picture of the skin epidermis of rats after the action of the gel "Solcoseryl".
Note: staining of hematoxylin-eosin. Uv. $\times 160$. In the field of view there are single blood-filled vessels of different calibers

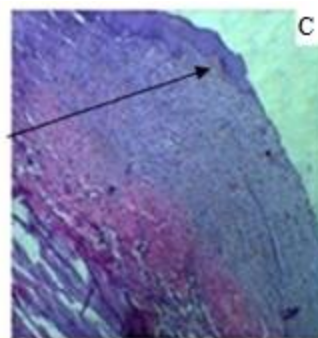


Fig. 8C. A histological picture of the epidermis of rat skin after exposure to chitosan gel with taurine and allantoin.
Note: staining of hematoxylin-eosin. Uv. $\times 160$.
Recovered epidermal shaft developing from the edges of the wound defect fills the damaged skin area.

Restored epidermal layer developing from the edges of the wound defect fills the damaged skin area. In the epidermis the maturity of granular, thorny, and basal layers in the absence of inflammatory infiltrate can be clearly recognized.

In the dermis there is lack of lymphohistiocytic infiltrate. In the granulation tissue the fibrous structures prevail, that is considered to be the criterion of maturity. The ChTA gel application caused the decreased level of substances of low and average molecular weight by 22.59% and 11.59% on the 14th and 28th day respectively in comparison with the control ($p < 0.05$) and by 13.37% and 7.41% in comparison with the "Solcoseryl" gel group ($p < 0.05$). Based on these data it can be assumed that the application of the ChTA gel contributes to decreased nonspecific signs of inflammation and post-burn intoxication.

When investigating the anti-inflammatory action of the chitosan gel with taurine and allantoin using the formalin test (a swollen rat leg) there has been stated that preliminary application of the chitosan gel with taurine and allantoin significantly reduced swelling of the limb by 13.9% in 30 minutes, by 16.6% in 180 minutes ($p < 0.05$) (Figure 9).

Thus, topical separate application of each component – taurine, chitosan, and allantoin – is reported to be less effective than combination of these substances in the gel dosage form. Preliminary application of the ChTA gel resulted in the reliable reduction of the limb swelling caused by the injection of formalin by 16.6% in 180 minutes ($p < 0.05$); this proves the occurrence of the additive effect due to the combination of active substances formulated in the gel. Strength of the anti-inflammatory action of the ChTA gel is slightly lower than that of the "Voltaren Emulgel", however, it is significantly higher than the anti-inflammatory action of the "Solcoseryl" gel and the "Levomekol" ointment.

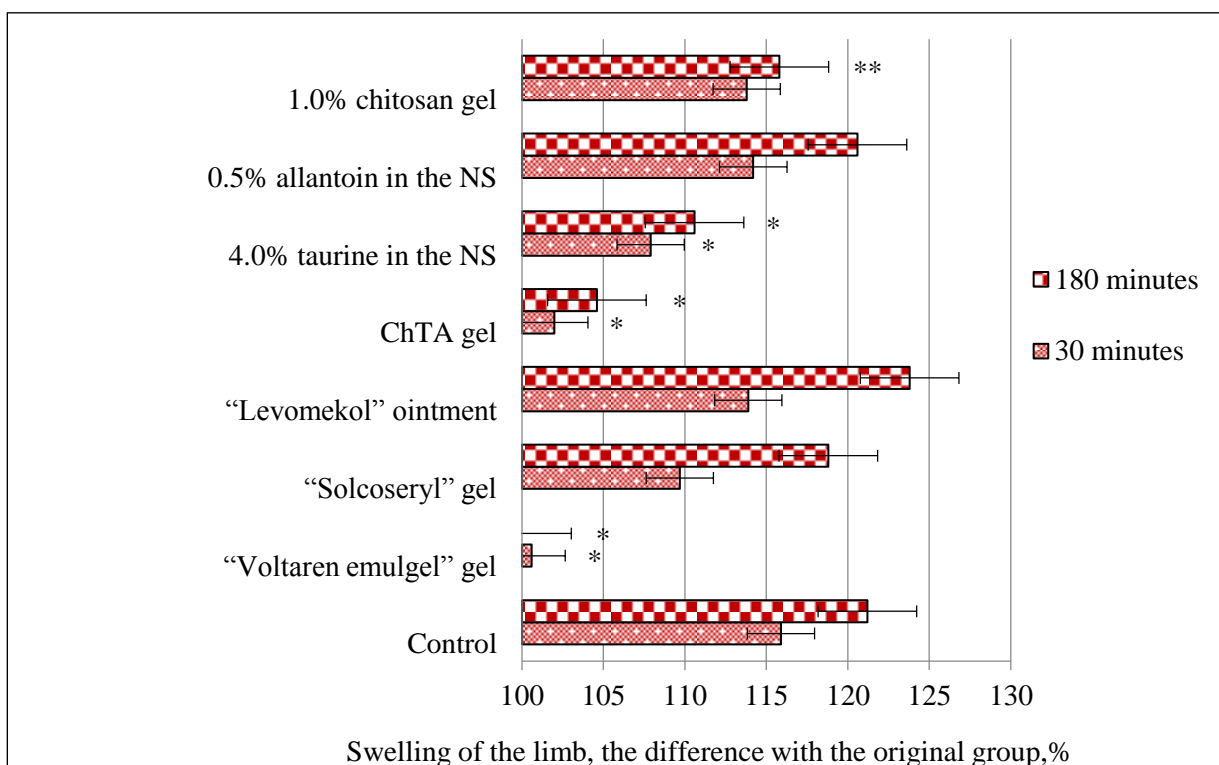


Fig. 9. Comparative evaluation of the anti-inflammatory activity of the ChTA gel, “Voltaren Emulgel”, “Solcoseryl” gel, 4.0% taurine solution, 0.5% allantoin solution, 1.0% chitosan gel on the model of formalin test (a swollen rat leg).

Note: * – P<0.05; ** – P<0.01 – statistical significance in comparison with the control

Investigations of the capillary-protective action of the chitosan gel with taurine and allantoin in the trypan blue exclusion test at the site of inflammation demonstrated that application of the ChTA gel relevantly

increased the time of appearance of staining by 40.0% and the time of distinct staining by 42.8% in comparison with the control (p<0.05) (Table 4).

Table 4

Impact of “Troxevasin” gel, ChTA gel, taurine and allantoin solution in the mono-composition on the reduction of vascular permeability in mice

Group of animals	Time of appearance of staining, sec.	Difference with the control, %	Time of distinct staining, sec.	Difference with the control, %
Control	81.17±0.75	-	122.33±1.03	-
“Troxevasin” gel	117.83±2.32*	45.2	173.67±2.50*	42.0
Gel HTA	113.67±0.82*	40.0	174.67±1.51*	42.8
Taurine 4,0% in saline	99.83±2.32*	23.0	162.00±3.58*	32.4
Allantoin 0,5% in saline	86.00±1.67*	6.0	127.50±1.64*	4.2
Gel chitosan 1,0%	83.17±1.94**	2.5	125.00±2.61**	2.2

Note: * – P<0.05, ** – P<0.01 – statistical significance in comparison with the control.

Thus, taurine, chitosan, and allantoin have slightly expressed capillary-protective action in mono-composition; whereas, using these substances in combination, formulated in the ChTA gel, more expressed action supporting the manifestation of additive effect is observed. Application of the ChTA gel provides reliable reduction of the capillary permeability in the trypan blue exclusion test by at least 40.0% (p<0.05) if compared to the control

group. This effect is comparable with the “Troxevisin” gel effect.

Discussion

Data obtained from scientific literature state that chitosan formulated in many dosage forms accelerates wound healing, manifests wound-healing effect at the all stages of the wound process; with that, it has haemostatic and antibacterial effect.

Leading mechanisms of the wound-healing action of chitosan are considered to be the ability to accelerate migration of neutrophils and macrophages, to particularly provide proliferation of fibroblasts and collagen synthesis, as well as to increase the level of granulation tissue in the wound area, to ensure granulation tissue formation, vascularization, fibroplasia, epithelization and wound contraction; this results in accelerated wound-healing without formation of a rough scar [19, 20, 21, 22].

Results obtained in this study conform to the data of scientific research studies that taurine and allantoin have wound-healing effect. Application of the preparations from the anti-oxidant group is known to contribute to reduced negative impact of free radicals on the wound process. Taurine as an antioxidant reduces the processes of free-radical oxidation and stabilizes the cytoplasmic membrane, increases cell vitality and proliferation, which, in turn, affects the inflammation and collagenogenesis and leads to acceleration of the wound-healing process due to synergetic, antioxidant and anti-apoptotic effects [23, 24]. Topical treatment of wounds by taurine is reported to result in the formation of connective fibers in the dermis, significantly increasing the wound-disruption strength and accelerating the process of epithelization, reduce the malondialdehyde and histamine level; this may result from the impact of taurine on inhibition of lipid peroxidation [10, 11]. Application of taurine for wound care in mice has been proved to cause the reliable increase of volume density of collagenic bundles, length and density of vessels and fibroblast number density in comparison with the control group [24]. Taurine has positive impact on the activity of phagocytosis and is recommended for use in the period of post-burn rehabilitation to increase immunoprotection [25].

As for allantoin, it accelerates the growth of connective tissue, bones, and cartilages, has an antioxidant and moderate anti-inflammatory effect [26], helps remove young keloid scars, is included as a compound in the sunburn protective creams. It has been histologically proved that allantoin provides restoration of the damaged skin; mechanisms of the allantoin wound healing action are considered to be regulation of inflammatory response by inhibiting immune cell chemotaxis in the wound area, prevention of reactive oxygen intermediate release, stimulation of fibroblast proliferation and matrix synthesis, ability to reduce the number of inflammatory cells, which leads to formation of more negligible scar similar to healthy skin [12, 15, 16].

The results obtained on the evaluation of anti-inflammatory action conform to the literature data of other researchers and support that taurine and chitosan have a slightly expressed anti-inflammatory effect. An anti-inflammatory effect of taurine is known to be related to neutralization of hypochlorous acid (HOCl), which is produced by neutrophils myeloperoxidase. Taurine reacts with HOCl with formation of taurine chloramines, the latter possessing an anti-inflammatory effect [27, 28, 29]. Taurine chloramine affects the activation of transcription nuclear factor-kappa B (NF- κ B) due to methionine oxidation in I κ B- α ; that is why, no heterodimer phosphorylation with I κ B-kinase and its translocation to the nucleus are observed. As a result the production of FNO- α , NO synthesis in macrophages and peroxynitrite synthesis decrease [30]. Chitosan, in turn, inhibits the cyclooxygenase-2 (COG-2) enzyme providing an anti-inflammatory action [22].

Conclusions

1. Physical and chemical compatibility of the components of the chitosan gel with taurine and allantoin has been proved in this study. Based on pharmacological, rheological, biopharmaceutical investigations optimal composition of the gel is determined as follows: chitosan – 1.0; taurine – 4.0; allantoin – 0.5; acetic acid – 0.5; purified water up to 100 g.

2. The chitosan gel with taurine and allantoin applied singly or repeatedly on the skin is reported to be of low toxicity (IV category of toxicity), does not result in the irritative, skin-resorptive and organotropic toxic effect.

3. The chitosan gel with taurine and allantoin manifests wound-healing properties increasing the wound-disruption strength in 1.5 times in comparison with the control in the treatment of planar wounds; in the treatment of the full-thickness skin wounds it provides complete healing 4 days earlier than in the control group and complete restoration of epithelium in the area of wound defect exceeding the efficiency of the “Levomekol” ointment by at least 40% and the “Solcoseryl” gel by 25%.

4. The chitosan gel with taurine and allantoin is reported to have an anti-burn effect, since, when compared to the control group, it provides complete healing 5 days earlier, significant decrease of the burn area by 29% on the 10th day, decrease of laboratory signs of inflammation and post-burn intoxication, improvement of regenerative processes and formation of slightly expressed post-burn scar exceeding the efficiency of the “Solcoseryl” gel by 28%, if taking into account the criterion of half-healing period.

5. The chitosan gel with taurine and allantoin is stated to provide significant reduction of the capillaries permeability in the trypan blue exclusion

test by at least 40% in the comparison with the control group; this result is comparable with the “Troxevasin” gel impact and supports reliable reduction of the limb swelling caused by formalin by 16.6% in 180 minutes. An anti-inflammatory effect of the chitosan gel with taurine and allantoin is less than that of the “Voltaren Emulgel”, however, it significantly exceeding the effect of the “Solcoseryl” gel and the “Levomekol” ointment.

Conflicts of Interest: The authors have no conflict of interest to declare.

References

1. Abaev Y.K. *Reference book of a surgeon. Wounds and wound infection.* (Rostov-na-Donu : Feniks, 2006), 427. (In Russian) [Full text]
2. Blatun L.A. Topical wound pharmacotherapy. *Surgery. N.I. Pirogov Journal.* 2011. № 4: 51-59. (In Russian) [eLIBRARY]
3. Skryabin K.G., Mihajlov S.N., Varlamov V.P. *Chitosan* (Moskva : Tsentr «Bioinzhenneriya» RAN, 2013), 591. (In Russian) [eLIBRARY]
4. Fedosov P.A., Provotorova S.I., Slivkin A.I., Podgornaya E.I., Kuznetsov V.A., Nikolaevskiy V.A. Justification of the choice of components and their compatibility for developing wound healing gel based on chitosan. *International scientific research journal.* 2015. Vol. 40, № 9: 83-85. (In Russian) [eLIBRARY] [Full text]
5. Fedosov P.A., Slivkin A.I., Nikolaevskij, V.A., Provotorova S.I., Buzlama A.V., Mihajlov E.V.. Study of the wound healing gel on the basis of chitosan with taurine and allantoin. *Current issues of science and education.* 2015. № 4, accessed May 01, 2017 <http://www.science-education.ru/127-21247> (In Russian) [eLIBRARY] [Full text]
6. Schneider L.A., Korber A., Grabbe S., Dissemond J. Influence of pH on wound-healing: a new perspective for wound-therapy? *Archives of Dermatological Research.* 2007. Vol. 298, № 9: 413-420. [PubMed] [Fulltext]
7. Francesko A., Tzanov T. Chitin, chitosan and derivatives for wound healing and tissue engineering. *Advances in biochemical engineering/biotechnology.* (Berlin : Springer, 2011), 1-27. [PubMed] [Fulltext]
8. Azuma K., Izumi R., Osaki T., Ifuku S., Morimoto M., Saimoto H. Chitin, chitosan, and its derivatives for wound healing: old and new materials. *Journal of Functional Biomaterials.* 2015. Vol. 6, № 1: 104-142. [PubMed] [Fulltext]
9. Fedosov P.A., Slivkin A.I., Nikolaevskij V.A., Buzlama A.V. Investigations of the acute toxicity, irritative and skin-resorptive effect of the chitosan gel with taurine and allantoin. *Reporter of the Voronezh State University. Series “Chemistry. Biology. Farmacy”.* 2015. № 4: 141-144. (In Russian) [eLIBRARY] [Full text]
10. Dincer S., Babül A., Erdogan D., Ozogul C., Dincer S.L. Effect of taurine on wound healing. *Amino Acids.* 1996. Vol. 10, № 1: 59-71. [PubMed] [Fulltext]
11. Degim Z., Çelebi N., Sayan H., Babül A., Erdoğan D., Take G. An investigation on skin wound healing in mice with a taurine-chitosan gel formulation. *Amino acids.* 2002. Vol. 22, № 2: 187-198. [PubMed] [Fulltext]
12. Araújo L.U., Grabe-Guimarães, A., Mosqueira, V.C., Carneiro C.L., Silva-BarcellosII N.M. Profile of wound healing process induced by allantoin. *Acta Cirurgica Brasileira.* 2010. Vol. 25, № 5: 460-461. [Fulltext]
13. Shestopalov A.V., Shkurat T.P., Mikashinovich Z.I., Kryzhanovskaia I.O., Bogacheva M.A., Lomteva S.V., Prokofev V.P., Guskov E.P. Biological functions of allantoin. *Biology Bulletin.* 2006. Vol. 33, № 5: 437-440. [PubMed] [Fulltext]
14. Becker L. C., Bergfeld, W.F., Belsito D.V., Klaassen C.D., Marks J.G., Shank R.C. Final report of the safety assessment of allantoin and its related complexes. *International Journal of Toxicology.* 2010. Vol. 29, № 3: 84-97. [PubMed] [Fulltext]
15. Szymanska E. Allantoin – healing and anti-inflammatory properties. *Pediatrics i Medycyna Rodzinna.* 2012. Vol. 8, № 1: 73-77. [Abstract]
16. Tosti A., Hexel D. Update in cosmetic dermatology. (Berlin : Springer, 2013), 214 [Abstract] [Fulltext]
17. Pat. 2611400 of the Russian Federation, IPC A61K31/722. Wound healing gel for the external use / Tupikin V.F., Slivkin A.I., Provotorova S.I., Fedosov P.A., Beleneva A.S., Veretennikova M.A. ; applicant and patentee ZAO VITC. 2015115143 from 23.04.2015 ; publ. 21.02.2017. (In Russian) [Fulltext]
18. Pat. 163084 of the Russian Federation, IPC A61B17/02. Mechanical wound tensiometer / Nikolayevsky V.A., Fedosov P.A., Podgornaja E.I., Frolov V.G. ; applicant and patentee Voronezh state University. 2015151598/14 from 01.12.2015 ; publ. 10.07.16. (In Russian) [Fulltext]
19. Kardas I., Struszczyk M.H., Kucharska M., Lambertus A.M., Jan E.G., Ciechańska D. Chitin and chitosan as functional biopolymers for industrial applications. *The European Polysaccharide Network of Excellence.* 2012.: 329-373. [Abstract] [Fulltext]
20. Dai T., Tanaka M., Huang Y., Hamblin M. Chitosan preparations for wounds and burns: antimicrobial and wound-healing effects. *Expert Review of Anti-infective Therapy.* 2011. Vol. 9, № 7: 857-879. [PubMed] [Fulltext]
21. Peng S., Liu W., Han B., Chang J., Li M., Zhi X. Effects of carboxymethyl-chitosan on wound healing in vivo and in vitro. *Journal of Ocean University of China.* 2011. Vol. 10, № 4: 369-378. [Abstract] [Fulltext]
22. Muzzarelli R.A., Muzzarelli C. Chitosan chemistry: relevance to the biomedical sciences. *Advances in polymer science.* 2005. Vol. 186: 151-209. [Abstract] [Fulltext]
23. Watson R.R., Zibadi S. Bioactive dietary factors and plant extracts in dermatology. (New York : Humana Press, 2013), 538. [Abstract] [Fulltext]

24. Ashkani-Esfahani S., Zarifi F., Asgari Q., Samadnejad A., Rafiee S., Noorafshan A. Taurine improves the wound healing process in cutaneous leishmaniasis in mice model, based on stereological parameters. *Advanced biomedical research*. 2014. Vol. 3, № 1: 1-5. [Abstract] [Fulltext]

25. Farriol M., Venereo Y., Rosselló J., Gomez P., Palao R., Orta X. Effects of taurine on polymorphonuclear phagocytosis activity in burned patients. *Amino acids*. 2012. Vol. 23, № 4: 441-445. [Abstract] [Fulltext]

26. Kovalenko, S.N., Baranova I.I. Development of the gel composition with thioctic acid and allantoin for the diabetic wounds care. *Reporter of the Kazakh national technical university*. 2014. № 1: 81–86. (In Russian) [Fulltext]

27. Marcinkiewicz J., Kurnyta M., Biedron R., Bobek M., Kontny E., Maśliński W. Anti-inflammatory effects of taurine derivatives (taurine chloramine, taurine bromamine, and taurolidine) are mediated by different mechanisms. *Advances in experimental medicine and biology*. 2006. Vol. 583: 481-492. [PubMed] [Fulltext]

28. Marcinkiewicz J., Kontny E. Taurine and inflammatory diseases. *Amino acids*. 2014. Vol. 46, № 1: 7-20. [PubMed] [Fulltext]

29. Fedosov P.A., Nikolaevskij V.A., Slivkin A.I., Buzlama A.V. Investigations of the anti-inflammatory and capillary-protective activity of the chitosan gel with taurine and allantoin. *Reporter of the Voronezh State University. Series "Chemistry. Biology. Pharmacy"*. 2016. № 4: 147-151. (In Russian) [Abstract] [Full text]

30. Makarova L.M., Pogorelyj V.E., Voronkov A.V., Novikova N.A. Update views on the role of taurine in the CNS activity. *Experimental and clinical pharmacology*. 2014. Vol. 77, № 5: 38-44. (In Russian) [Abstract] [Full text]

Fedosov Pavel Alexandrovich, Assistance Lecturer, Department of Pharmacology, e-mail: fedosov91@gmail.com. Conducting experiments on the main part of the work 85%, writing and editing the article.

Nikolaevsky Vladimir Anatolievich, Professor, Department of Pharmacology, Holder of Habilitation Degree in Medicine, Professor, e-mail: nycolaeovsky@pharm.vsu.ru. A scientific supervisor, drawing up the design of the work and working out the details of experiments on the experimental part of the work, in particular in pharmacology.

Chernov Yuri Nikolaevich, Professor, Department of Clinical Pharmacology, Holder of Habilitation Degree in Medicine, Professor, e-mail: nclin.pharm@vsmaburdenko.ru. A scientific consultant of this work, in all the studies helped in interpreting the results.

Buzlama Anna Vitalievna, Head of the Department of Pharmacology, Holder of Habilitation Degree in Medicine, Associate Professor, e-mail: buzlama@pharm.vsu.ru. Assisted in the writing of this work, in particular in building logical relationships between experiments.

Slivkin Alexey Ivanovich, Head of the Department of Pharmaceutical Chemistry and Pharmaceutical Technology, Holder of Habilitation Degree in Medicine, Professor, e-mail: slivkin@pharm.vsu.ru. The ideological inspirer of this work, assisted in carrying out experiments in pharmaceutical chemistry.

Provotorova Svetlana Ilinichna, Associate Professor, Department of Pharmaceutical Chemistry and Pharmaceutical Technology, Candidate of Pharmaceutical Sciences, e-mail: provotorova-svetlana@mail.ru. Assisted in carrying out experiments in pharmaceutical technology, and writing part of the work on pharmaceutical technology.

Received: April, 17, 2017

Accepted: May, 30, 2017

Available online: June, 27, 2017