



Study to Investigate the anti-inflammatory effect of Codelac® Broncho with Thymus Serpyllum (elixir) in comparison with reference drug Fenspiride (syrup) using acute Carrageenan-induced Paw Inflammation Model

Pavel D. Kolesnichenko¹, Anna A. Peresyphkina¹, Artem A. Poromov¹, Elena N. Kareva², Alexey V. Tverskoi¹, Alexey N. Demidenko¹

1 I. Mechnikov Research Institute for Vaccines and Sera, 5a Maly Kozenyi Lane, Moscow 105064 Russia

2 Pirogov Russian National Research Medical University, 1 Ostrovitianov St., Moscow 117997 Russia

Corresponding author: Anna A. Peresyphkina (anny_87_@mail.ru)

Academic editor: Oleg Gudyrev ♦ Received 21 December 2018 ♦ Accepted 12 March 2019 ♦ Published 27 March 2019

Citation: Kolesnichenko PD, Peresyphkina AA, Poromov AA, Kareva EN, Tverskoi AV, Demidenko AN (2019) Study to Investigate the anti-inflammatory effect of Codelac® Broncho with Thymus Serpyllum (elixir) in comparison with reference drug Fenspiride (syrup) using acute Carrageenan-induced Paw Inflammation Model. Research Results in Pharmacology 5(1): 45–52. <https://doi.org/10.3897/rrpharmacology.5.33233>

Abstract

Introduction: Evaluation of anti-inflammatory action of Codelac® Broncho with *Thymus Serpyllum* (elixir) in comparison with Fenspiride was carried out on the model of acute carrageenan inflammation of the paws in rats.

Materials and methods: Edema was caused by subplantar injection of 0.1 ml of 1% λ -carrageenan gel into the hind paw. The severity of edema was assessed by using 37140 plethysmometer (UGO BASILE, Italy). The measurements were performed before edema induction and 1, 2, 4, 12, 24, 48, 72, 96 and 120 hours afterwards. Anti-inflammatory activity of the drugs was also evaluated based on the analysis of rats' blood, C-reactive protein concentration and histological examination results.

Results and discussion: A decrease in the paw volume increment was revealed in the group with the studied drug in comparison with the group with the carrageenan edema model (control) 4, 12, 24 hours after injection of carrageenan ($p < 0.05$). As a result of plethysmometry, a more pronounced anti-inflammatory effect of the studied drug than that of Fenspiride was revealed. There was a significant decrease in the levels of leukocytes ($p < 0.05$), lymphocytes ($p < 0.05$), monocytes ($p < 0.05$) and neutrophils ($p < 0.05$) in the group with the studied drug compared to those the the control 48 hours after the initiation of edema, while in the group with Fenspiride, there was only a decrease in the levels of leukocytes ($p < 0.05$) and lymphocytes ($p < 0.05$). There were no differences in the concentration of C-reactive protein between the groups.

Conclusion: The obtained data indicate a more pronounced anti-inflammatory activity of Codelac® Broncho with *Thymus Serpyllum* in comparison with Fenspiride, on the model of acute carrageenan inflammation of the paw in rats.

Keywords

Codelac® Broncho with *Thymus Serpyllum* (elixir), anti-inflammatory activity, carrageenan edema, acute exudative inflammation.

Introduction

Acute inflammation is characterized by rapid development of local inflammatory reaction in response to phlogogen and systemic reaction in the acute-phase response (Enikeev et al. 2017). Inflammation is the main adaptive process underlying many pathological conditions (flu, asthma, pneumonia, arthritis, etc.). At the heart of the inflammatory response is a complex of cellular and humoral factors produced in response to damage and aimed at its relief (Demyanov and Kotov 2003, Liang et al. 2015).

At the heart of the exudation phase is the reaction of the microcirculatory bed in the form of malperfusion at the site of injury, increased permeability of the vascular wall, exudation of plasma and emigration of blood cells from the vascular lumen to the surrounding tissues and phagocytosis. In the initial stages of the exudative phase, in response to perturbed vascular endothelium and disrupted platelets, there is release of endothelins, catecholamines, thromboxane A2 and leukotrienes, the vasoconstrictor tone reflexively increases, and at the site of injury there develops a short-term local spasm of arterioles lasting from a few seconds to a few minutes (Poryadin 2014).

As a result of the activating effect of IL-1, IL-8 and other pro-inflammatory mediators on neutrophils, there is an increase in the synthesis and isolation of lysosomal enzymes and leukotrienes, activation of phagocytosis, as well as a respiratory explosion with neutrophil degranulation. Under the influence of neutrophils, there is a change in the cell population in the focus of inflammation with the accumulation of macrophages there (Serebryannikov and Seminsky 2014).

Fenspiride hydrochloride has a complex anti-inflammatory effect on the mucous membrane of respiratory tract (RT) in acute respiratory infection (ARI). Acting on the metabolism of arachidonic acid, Fenspiride reduces the formation of prostaglandins and leukotrienes, being an antagonist of H1-histamine receptors and $\alpha 1$ -receptors, reduces bronchial hyperreactivity, and prevents bronchoconstriction (Erdes 2004, Ovcharenko and Glukhareva 2009, Sokolov 2003, Tatochenko 2007).

In addition to ambroxol, which has a mucolytic and expectorant effect, the composition of Codelac® Broncho with *Thymus Serpyllum* (elixir) includes sodium glycyrrhizinate and thyme extract, each of which has an anti-inflammatory effect (Bernela et al. 2016, Marianecchi et al. 2014, Qadir et al. 2016). Their combined application is assumed to lead to synergy, as a result of which Codelac® Broncho with *Thymus Serpyllum* (elixir) is able to have a pronounced anti-inflammatory effect.

It should be noted that traditional antitussives have no anti-inflammatory activity. The combination of mucolytic, expectorant and anti-inflammatory effects of Codelac® Broncho with *Thymus Serpyllum* (elixir) should lead to a more pronounced therapeutic efficacy in the treatment of bronchitis, COPD, pneumonia, and bronchiectasis.

In connection with the above, it was relevant to study the anti-inflammatory activity of the combined drug Codelac® Broncho with *Thymus Serpyllum* (elixir), con-

taining two components with anti-inflammatory action (in particular, of plant origin), in comparison with the drug containing anti-inflammatory monocomponent – Fenspiride (syrup), on the model of acute carrageenan inflammation of the paw in rats.

Objective: to study the anti-inflammatory activity of Codelac® Broncho with *Thymus Serpyllum* (elixir), in comparison with Fenspiride (syrup), on the model of acute carrageenan inflammation of the paw in rats.

Materials and methods

The experiments were performed in Wistar rats weighing 225–275 g, without any external signs of disease, and which had passed through quarantine. The ethical principles of handling laboratory animals were observed in accordance with the European Convention for the Protection of Vertebrate Animals Used for Experimental and Other Scientific Purposes, CETS No. 123. The experiment included the following groups: the first (n=10) – control (model of carrageenan edema), the second (n=10) – with the administration of Codelac® Broncho with *Thymus Serpyllum* (elixir) against the background of the simulated carrageenan edema, the third (n=10) – with the administration of Fenspiride against the background of the simulated carrageenan edema. Codelac® Broncho with *Thymus Serpyllum* (elixir) (OTCPharm PJSC) was injected to rats intragastrically in a volume of 0.17 ml 4 times a day. Fenspiride (Erispirus syrup, 2 mg/ml, SANDOZ) was injected intragastrically in a volume of 0.29 ml 4 times a day.

Edema was caused by subplantar injection (under the plantar aponeurosis) of 0.1 ml of 1% λ -carrageenan aqueous gel (SIGMA 22049 λ -Carrageenan plant mucopolysaccharide, SIGMA-ALDRICH), which had been prepared before the injection (Mironov 2012), into the right hind paw of the rat. The severity of edema was assessed by measuring the volume of animals' paws using 37140-plethysmometer (UGO BASILE, Italy). Measurements were performed before edema induction (initial volume) and 1, 2, 4, 12, 24, 48, 72, 96 and 120 hours after subplantar injection of carrageenan.

The anti-inflammatory activity of the drugs was evaluated by a decrease in the paw volume increment, expressed as a percentage of the initial volume, compared to the control group. The volume of paws of the animal before the injection of carrageenan was taken as the initial volume (100%). A share (%) of paw volume increment = [(volume after injection of carrageenan at a certain moment – initial volume) / initial volume] \times 100.

For cytological analysis, blood was taken from the rats prior to and 4 h, 12 h, 24 h, 48 h, and 120 hours after the injection of carrageenan. The concentration of C-reactive protein was determined before and 4 hours and 24 hours after the injection of carrageenan.

The histological picture was described according to the data obtained in one animal from each group 4 and 24 hours after the inflammation induction.

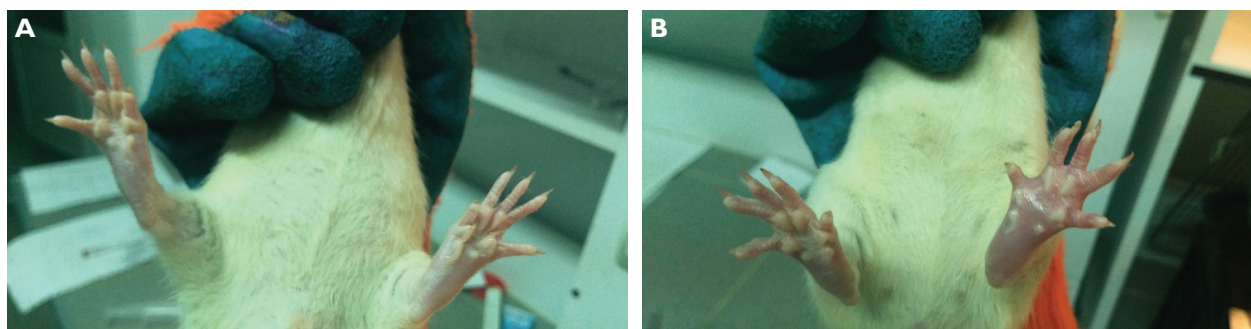


Figure 1. General view of the hind paw 3 hours after the initiation of carrageenan edema with the injection of: A – Codelac® Broncho with Thymus Serpyllum (elixir), B – Fenspiride (syrup).

For all the data obtained, descriptive statistics were used, and the data were checked for normal distribution. A distribution type was determined by using the Shapiro-Wilk criterion. In case of normal distribution, the mean value (M) and standard error of the mean (SEM) were calculated. Between-group differences were analyzed by parametric (t-Student criterion) or non-parametric (Mann-Whitney test) methods, depending on a type of distribution. Differences were determined at a 0.05 significance level. Statistical analyses were performed using STATISTICA 10.0 software.

Results and discussion

Injection of 0.1 ml of 1% aqueous gel of λ- carrageenan under plantar aponeurosis led to the development of a pronounced inflammatory reaction, with edema reaching the greatest degree of severity about 3 hours after the injection. A general view of the hind paws of rats 3 hours after the initiation of carrageenan edema in the groups with correction by the studied drug and the comparison drug is shown in Figure 1.

Table 1 presents the results obtained when calculating the volume of edema at different time points in the study groups.

In case of injecting Codelac® Broncho with Thymus Serpyllum, there was a significant decrease in the paw volume increment compared to that in the control group, starting with 4 hours after the initiation of edema, by 42.4% ($p < 0.05$), while in the group with the injection of the comparison drug, there were no significant differences observed from the values of the control group. In the group with the injection Fenspiride, 8 hours after the induction of edema, there was observed a significant decrease in the paw volume increments in comparison with the control group – by 40.6% ($p < 0.05$), while in the group with the injection of the studied drug there were not significant differences observed from the control. In the group with Codelac® Broncho with Thymus Serpyllum, 12 and 24 hours after the injection of carrageenan, there was a decrease in the increase in the paw volume increments, which indicated the anti-inflammatory activ-

Table 1. Effects of Codelac® Broncho with Thymus Serpyllum (elixir) and Fenspiride (syrup) on the Change of Paw Volume Increment with the Simulated Carrageenan Edema (m±SEM; n=10), % of initial volume.

Time	Fenspiride (syrup)	Codelac® Broncho with Thymus Serpyllum (elixir)	Control
1 h	7.54 ± 1.39	6.87 ± 1.28	9.59 ± 2.03
2 h	13.48 ± 1.39	9.84 ± 1.11	14.12 ± 2.31
4 h	11.61 ± 1.71	9.48 ± 1.68*	16.46 ± 2.02
8 h	10.28 ± 1.10*	12.92 ± 6.01	17.32 ± 1.52
12 h	10.51 ± 1.95*	9.54 ± 2.01*	18.07 ± 2.20
24 h	2.07 ± 1.04*	0.69 ± 1.23*	9.50 ± 2.37
48 h	1.18 ± 0.59	0.46 ± 0.90	2.72 ± 1.47
72 h	0	0	0
96 h	0	0	0
120 h	0	0	0

Note: * - $p < 0.05$ compared to the control group.

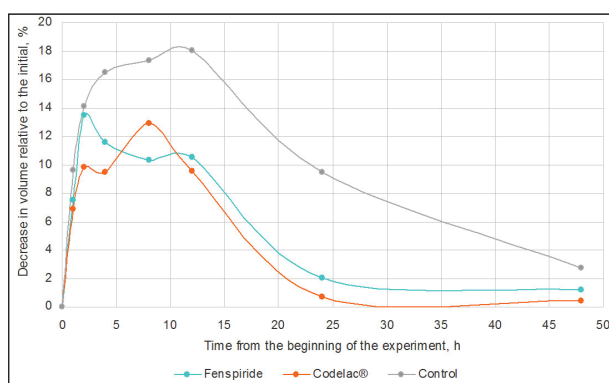


Figure 2. The influence of Codelac® Broncho with Thymus Serpyllum (elixir) and Fenspiride (syrup) on change in paw volume increments on the model of acute carrageenan inflammation of the paw.

ity of the studied drug on the model of acute carrageenan inflammation of the paw in rats (Fig. 2). Starting from 72 hours after the initiation of edema and further, there was normalization of indicators in all groups.

The analysis of rats' blood revealed a significant decrease in the levels of leukocytes ($p < 0.05$), lymphocytes

Table 2. The Results of the Analysis of Blood in Case of Injecting Codelac® Broncho with Thymus Serpyllum (elixir) and Fenspiride (syrup) Against the Background of Acute Carrageenan Inflammation of the Paw in Rats (M ± SEM).

Indicators	Initial			4 hours after initiation of edema		
	Control	Codelac®	Fenspiride	Control	Codelac®	Fenspiride
leukocytes *10x9/L	7.30±0.65	7.44±0.46	7.66±0.29	7.23±0.69	9.43±0.82	9.95±1.03
lymphocytes *10x9/L	3.29±0.38	3.44±0.26	3.66±0.29	3.49±0.43	4.38±0.39	4.53±0.40
monocytes *10x9/L	0.43±0.06	0.50±0.07	0.35±0.03	0.38±0.09	0.30±0.03	0.43±0.07
basophils *10x9/L	0.03±0.02	0.04±0.02	0.05±0.02	0.04±0.01	0.03±0.02	0.05±0.02
eosinophils *10x9/L	0.18±0.03	0.13±0.02	0.21±0.01	0.18±0.02	0.18±0.02	0.23±0.03
neutrophils *10x9/L	3.39±0.42	3.34±0.38	3.39±0.21	3.15±0.51	4.55±0.43	4.73±0.54
neutrophils, %	46.44±3.75	44.54±3.04	44.52±3.12	43.2±2.1	48.10±0.90	47.26±0.78
lymphocytes, %	45.14±3.43	46.59±3.09	47.50±2.95	48.5±1.5	46.35±0.40	45.89±0.93
eosinophils, %	2.36±0.34	1.68±0.17	2.82±0.24	2.48±0.26	1.98±0.30	2.24±0.28
basophils, %	0.32±0.22	0.46±0.23	0.62±0.24	0.50±0.10	0.28±0.20	0.41±0.17
monocytes, %	5.74±0.67	6.74±0.84	4.54±0.34	11.1±2.3	3.29±0.36	4.20±0.48
Indicators	12 hours after initiation of edema			24 hours after initiation of edema		
	Control	Codelac®	Fenspiride	Control	Codelac®	Fenspiride
leukocytes *10x9/L	7.18±0.69	7.20±0.68	8.28±0.85	11.38±1.42	8.96±0.78	9.10±0.74
lymphocytes *10x9/L	2.98±0.29	3.33±0.29	3.75±0.44	4.98±0.69	4.14±0.46	3.78±0.33
monocytes *10x9/L	0.45±0.08	0.40±0.05	0.55±0.11	0.69±0.14	0.55±0.07	0.51±0.07
basophils *10x9/L	0.00±0.00	0.03±0.02	0.00±0.00	0.05±0.02	0.03±0.02	0.03±0.02
eosinophils *10x9/L	0.13±0.02	0.18±0.02	0.20±0.03	0.23±0.05	0.16±0.02	0.20±0.03
neutrophils *10x9/L	3.63±0.40	3.28±0.38	3.78±0.29	5.44±0.59	4.09±0.43	4.59±0.35
neutrophils, %	50.57±2.18	44.95±1.54	46.73±1.91	48.36±1.84	45.81±2.73	50.72±1.39
lymphocytes, %	41.74±2.23	46.45±0.76	44.81±0.93	43.44±1.67	45.96±2.36	41.36±1.52
eosinophils, %	1.76±0.17	2.67±0.44	2.36±0.13	1.95±0.29	1.85±0.20	2.14±0.17
basophils, %	0.00±0.00	0.29±0.21	0.00±0.00	0.42±0.18	0.24±0.16	0.22±0.14
monocytes, %	5.93±0.65	5.65±0.69	6.09±0.99	5.83±0.50	6.14±0.65	5.56±0.62
Indicators	48 hours after initiation of edema			120 hours after initiation of edema		
	Control	Codelac®	Fenspiride	Control	Codelac®	Fenspiride
leukocytes *10x9/L	21.04±1.20	14.75±1.32*	16.28±0.93*	17.74±1.58	14.61±1.75	13.20±1.43
lymphocytes *10x9/L	9.64±0.50	6.89±0.74*	6.76±0.40*	8.71±1.13	6.81±1.00	6.36±0.68
monocytes *10x9/L	0.91±0.10	0.58±0.05*	0.80±0.09	0.74±0.07	0.75±0.15	0.61±0.09
basophils *10x9/L	0.08±0.02	0.06±0.02	0.05±0.02	0.10±0.02	0.05±0.03	0.08±0.03
eosinophils *10x9/L	0.39±0.02	0.30±0.04	0.35±0.04	0.38±0.05	0.31±0.04	0.28±0.04
neutrophils *10x9/L	10.03±1.21	6.93±0.64*	8.31±0.60	7.81±0.80	6.69±0.72	5.88±0.68
neutrophils, %	46.65±3.29	47.21±2.12	50.94±1.60	44.59±2.99	46.58±2.34	44.31±1.04
lymphocytes, %	46.63±2.95	46.20±2.14	41.69±1.45	48.38±2.80	45.95±2.17	48.36±1.21
eosinophils, %	1.88±0.14	2.04±0.18	2.15±0.20	2.10±0.18	2.15±0.18	2.12±0.22
basophils, %	0.38±0.09	0.40±0.12	0.29±0.11	0.58±0.10	0.29±0.16	0.53±0.16
monocytes, %	4.46±0.50	4.15±0.55	4.93±0.48	4.35±0.51	5.03±0.64	4.67±0.49

Note: * - $p < 0.05$ compared to the control group.

Table 3. The C-reactive Protein Concentration When Using Codelac® Broncho with Thymus Serpyllum (elixir) and Fenspiride (syrup) on the Model of Acute Carrageenan Inflammation of the Paw in Rats (M ± SEM).

Groups	Time of blood sampling (after injection of carrageenan)		
	Before injection	4 h	24 h
Control	0.13±0.03	0.15±0.01	0.17±0.02
Codelac® Broncho with Thymus Serpyllum (elixir)	0.15±0.02	0.16±0.01	0.18±0.02
Fenspiride (syrup)	0.17±0.03	0.15±0.01	0.18±0.03

($p < 0.05$), monocytes ($p < 0.05$) and neutrophils ($p < 0.05$) in comparison with those in the control group 48 hours after the initiation of edema with the correction by Codelac® Broncho with **Thymus Serpyllum** (elixir), while in the group with the correction by **Fenspiride** (syrup), there was only a significant decrease in the levels of leukocytes ($p < 0.05$) and lymphocytes ($p < 0.05$) (Table 2). The data obtained indicate a more pronounced anti-inflammatory activity of Codelac® Broncho with **Thymus Serpyllum** (elixir) in comparison with **Fenspiride** (syrup).

There were no significant differences in the concentration of C-reactive protein in the groups treated with the studied drug and the comparison drug (Table 3).

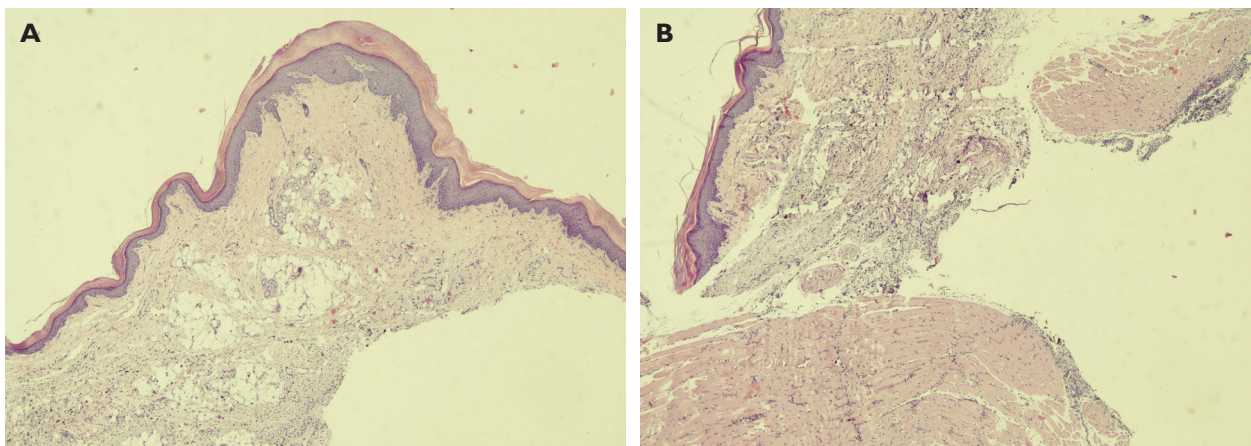


Figure 3. Histological picture 4 hours after initiation of carrageenan edema in the control group. Stained with haematoxylin and eosin. $\times 40$.

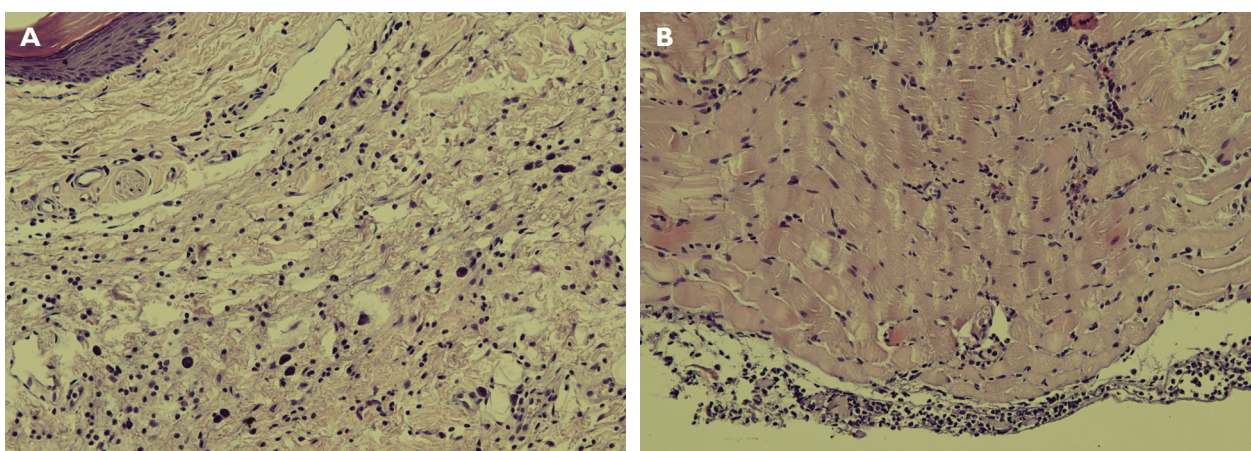


Figure 4. Histological picture 4 hours after initiation of carrageenan edema in the control group. Stained with haematoxylin and eosin. $\times 200$.

The following histological picture was observed in the control group 4 hours after initiation of edema. The epidermis of the plantar surface of the foot had a usual structure, without abnormalities. The corneal layer was well-defined. The skin itself consisted of the papillary and reticular layers of the conventional structure. The hypodermis consisted of mainly subcutaneous fat tissue with signs of moderate inflammation, vascular and capillary plethora. The underlying muscular tissue had signs of acute purulent inflammation in the form of purulent (fibrinous-purulent) deposits on muscular perimysium and moderate purulent infiltration within the muscle (Figs 3, 4).

In the group with the treatment of edema by Codelac® Broncho with *Thymus Serpyllum* (elixir), 4 hours after initiation of carrageenan edema, the epidermis plantar surface of the foot was of the usual structure, without abnormalities. The corneal layer was well defined. The skin itself consisted of the papillary and reticular layers of the conventional structure. Hypodermis consisted of mainly subcutaneous fat tissue with signs of mild inflammation. The underlying muscular tissue had signs of acute mild inflammation, with severe inflammation in the form of

purulent (fibrinous-purulent) deposits on muscular perimysium as viewed from the hypodermis (Fig. 5).

In the group with the treatment of edema by *Fenspiride*, 4 hours after initiation of carrageenan edema, the epidermis of the plantar surface of the foot was of the usual structure, without abnormalities. The corneal layer was well-defined. The skin itself consisted of the papillary and reticular layers of the conventional structure. The hypodermis consisted of mainly subcutaneous fat tissue with signs of severe inflammation. The underlying muscular tissue had no signs of acute inflammation (Fig. 6).

In the control group 24 hours after the initiation of edema, the histological examination revealed the following: the dermis and epidermis of the plantar surface of the foot were of the usual structure, without abnormalities. The corneal layer was well-defined. The hypodermis had signs of an acute purulent inflammation, microabscess formation, vascular and capillary plethora, and fibrinous thrombi in a number of venous lumens. The underlying muscular tissue had a general purulent inflammation (Fig. 7).

In the group with the treatment of edema by Codelac® Broncho with *Thymus Serpyllum* (elixir), 24 h after initi-

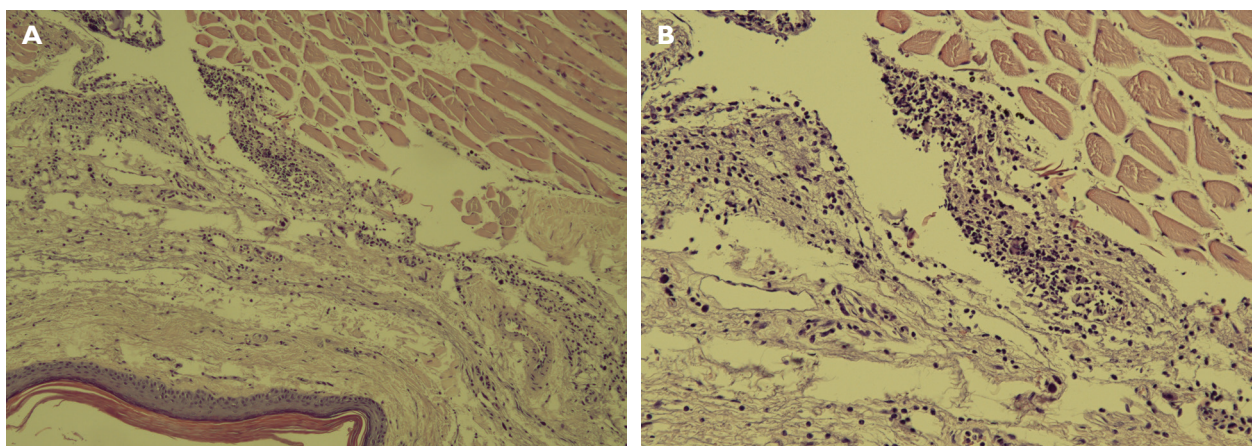


Figure 5. Histological picture 4 hours after initiation of carrageenan edema in the group with the treatment by Codelac® Broncho with *Thymus Serpyllum* (elixir). Stained with haematoxylin and eosin. $\times 100$ (A), $\times 200$ (B).

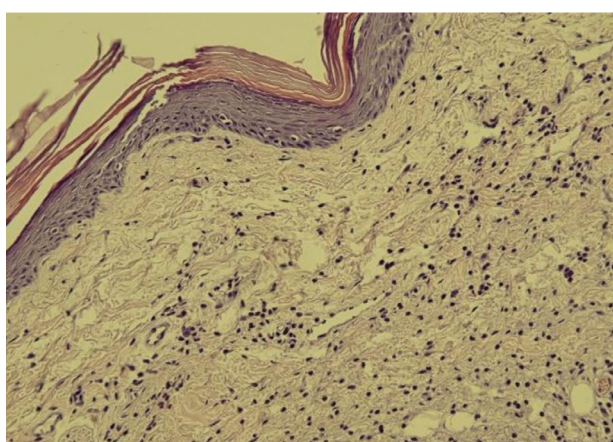


Figure 6. Histological picture 4 hours after initiation of carrageenan edema in group with the treatment by Fenspiride. Stained with haematoxylin and eosin. $\times 200$.

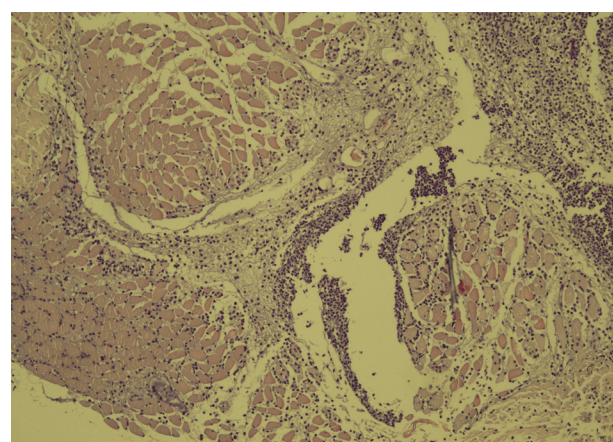


Figure 7. Histological picture 24 hours after initiation of carrageenan edema in the group with the treatment by Fenspiride. Stained with haematoxylin and eosin. $\times 100$.

ation of carrageenan edema, the dermis and epidermis of the plantar surface of the foot were of normal structure, without abnormalities. The corneal layer was well-defined. The hypodermis had signs of a mild inflammation. The underlying muscular tissue had no signs of acute inflammation (Fig. 8).

In the group with the treatment of edema by **Fenspiride**, 24 h after initiation of carrageenan edema, the dermis and epidermis of the plantar surface of the foot were of normal structure, without abnormalities. The corneal layer was well-defined. The hypodermis had signs of an acute diffuse local purulent inflammation with microabscess formation. There were fibrinous thrombi in the veins. The underlying muscular tissue had signs of incipient inflammation (Fig. 9).

Thus, the results of a comprehensive assessment, including the data of plethysmometric study, blood analysis and histological study, showed the presence of a pronounced anti-inflammatory effect of Codelac® Broncho with **Thymus Serpyllum** (elixir), exceeding the effects of

the comparison drug **Fenspiride** (syrup) on the model of acute inflammation of the paw in rats.

In most cases, the etiological factor of inflammation of the mucous membrane of the respiratory system is viruses and viral-bacterial associations. It is important to effectively influence local protection factors in the early stages of the disease to prevent disease progression, spread and complications. Considering the pathogenesis of the infectious process, along with etiotropic agents in the treatment of acute respiratory infections (ARI), it is important to use drugs that quickly reduce edema and hyperemia of the mucous membrane, eliminate cough, adjust sputum production and improve its discharge, prevent the development of hyperreactivity and irreversible changes in the mucous membrane of the respiratory tract (RT). RT has abundant innervation of C-fibers and A δ -fibers of sensory neurons located in the jugular, nodose, trigeminal ganglia, as well as in the ganglia of the posterior roots of the spinal cord. Stimulation of these fibers leads to the release of inflammatory neuropeptides

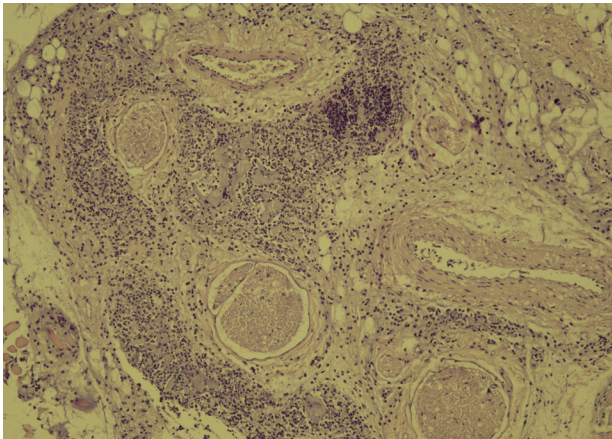


Figure 8. Histological picture 24 hours after initiation of carrageenan edema in the group with the treatment by Codelac® Broncho with *Thymus Serpyllum* (elixir). Stained with haematoxylin and eosin. $\times 100$.

into the respiratory tract, such as substance P, CGRP and neurokinin A, which in turn induce bronchospasm, vasodilation, immune cell recruitment and modulation of the inflammatory response. All this is manifested in the form of cough, an increased mucus production, rapid breathing, aimed at the elimination of the irritant. Long-term inflammation due to constant exposure to the irritant, or diseases such as cystic fibrosis, eventually lead to chronic cough, COPD, asthma and reactive airway dysfunction syndrome (Bautista et al. 2013).

Anti-inflammatory effect of Codelac® Broncho with *Thymus Serpyllum* is determined by the action of glycyrrate (glycyrrhizic acid and its salts). Glycyrrhizic acid (GA), undergoing metabolic transformations in the body, has a corticosteroid-like effect, resulted from its moderate stimulation of the adrenal cortex. GA and its aglycone enhance the effect of exogenous hormones of the adrenal cortex, inhibit oxidative phosphorylation and biosynthesis of sulfated mucopolysaccharides which reduce the activity of phospholipase A2, increase the glutamine transaminase activity. GA and its derivatives affect the cascade of arachidonic acid in the same way as NSAIDs, inhibiting the biosynthesis of prostaglandins. Thus, ammonium glycyrrhizinate suppresses the formation of prostaglandins E2 and F2 α in lungs and kidneys of mice. GA and glycyrrhetic acid inhibit the synthesis of prostoglandin E2 by activated macrophages; a similar process occurs in the culture of exudative cells. Anti-inflammatory properties of GA are due to its effect on inflammatory mediators – neutrophils. In particular, GA inhibits the release of singlet oxygen, hydrogen peroxide and OH ions in dose-dependent form by neutrophils (Tolstikov et al. 1997).

Extract of creeping thyme (Thytnus) contains a complex of biologically active substances with expectorant, anti-inflammatory, and antimicrobial effects. Due to the thyme having thymol and carvacrol, thyme-based preparations are effective in inflammatory processes caused by

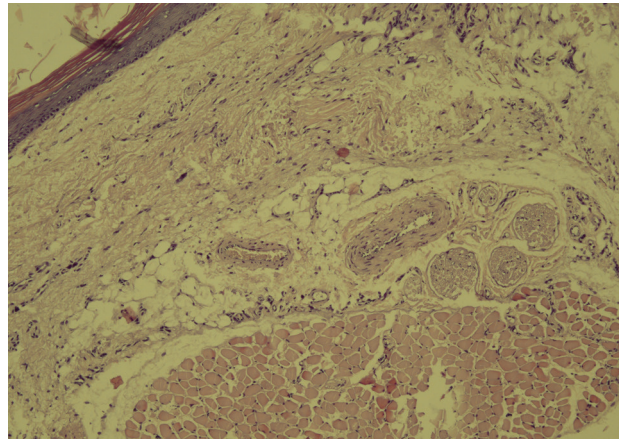


Figure 9. Histological picture in 24 hours after initiation of carrageenan edema in the group with correction by Fenspiride. Stained with haematoxylin and eosin. $\times 100$.

microflora resistant to antibiotics. Thyme preparations are used to treat inflammatory diseases of the oral cavity and pharynx, laryngitis, tracheitis, bronchitis and bronchopneumonia (Sokolov 2000).

Conclusion

The study revealed the following:

- there was a significant decrease in paw volume increment in the group with the treatment of carrageenan edema by Codelac® Broncho with *Thymus Serpyllum* (elixir) in comparison with the group with the model of carrageenan edema (control) 4, 12, 24 hours after the injection of carragenine ($p < 0.05$). The plethysmometric study revealed a more pronounced anti-inflammatory effect of the studied drug than the comparison drug *Fenspiride* (syrup), within the specified time frame;
- there was a significant decrease in the levels of leukocytes ($p < 0.05$), lymphocytes ($p < 0.05$), monocytes ($p < 0.05$) and neutrophils ($p < 0.05$) compared to those in the control group 48 hours after the initiation of edema when administering Codelac® Broncho with *Thymus Serpyllum* (elixir), while in the group with the injection of *Fenspiride* (syrup) there was only a significant decrease in the levels of leukocytes ($p < 0.05$) and lymphocytes ($p < 0.05$);
- in the groups with the injection of the studied drug and the comparison drug, there were no significant differences in the concentration of C-reactive protein in comparison with the control group;
- the histological study confirmed the presence of a more pronounced anti-inflammatory activity of Codelac® Broncho with *Thymus Serpyllum* (elixir), surpassing the effects of *Fenspiride* (syrup) on the model of acute carrageenan inflammation of the paw in rats 4 and 24 hours after initiation of edema.

Conflict of interests

The authors have no conflict of interest to declare.

References

- Bautista DM, Pellegrino M, Tsunozaki M (2013) TRPA1: A gatekeeper for inflammation. *Annual Review of Physiology* 75: 181–200. <https://doi.org/10.1146/annurev-physiol-030212-183811> [PubMed]
- Bernela M, Ahuja M, Thakur R (2016) Enhancement of anti-inflammatory activity of glycyrrhizic acid by encapsulation in chitosan-katira gum nanoparticles. *European Journal of Pharmaceutics and Biopharmaceutics* 105: 141–147. <https://doi.org/10.1016/j.ejpb.2016.06.003> [PubMed]
- Cytokines and Inflammation 3: 20–35. [in Russian]
- Demyanov AV, Kotov AYu (2003) Diagnostic value of cytokine levels research in clinical practice.
- Enikeev DA, Khisamov EN, Pavlov VN, Nurgalieva EA, Farshatova ER, Trubilin DV, Baiburina GA, Lehmus VI, Khalitova GG, Enikeeva OA (2017) Introduction to clinical pathophysiology. Typical pathological processes: tutorial. Ufa: Publishing House of Bashkir State Medical University, 164 pp. [in Russian]
- Erdes SI (2004) Pathogenetic bases of application and efficiency of fenspiride in pediatric practice. *Current Pediatrics [Voprosy Sovremennoi Pediatrii]* 4(3): 46–50. [in Russian]
- Liang PY, Diao LH, Huang CY, Lian RC, Chen X, Li GG, Zhao J, Li YY, He XB, Zeng Y (2015) The pro-inflammatory and anti-inflammatory cytokine profile in peripheral blood of women with recurrent implantation failure. *Reproductive Biomedicine Online* 31(6): 823–826. <https://doi.org/10.1016/j.rbmo.2015.08.009> [PubMed]
- Marianecci C, Rinaldi F, Di Marzio L, Mastriota M, Pieretti S, Celia C, Paolino D, Iannone M, Fresta M, Carafa M (2014) Ammonium glycyrrhizinate-loaded niosomes as a potential nanotherapeutic system for anti-inflammatory activity in murine models. *International Journal of Nanomedicine* 9: 635–651. <https://doi.org/10.2147/IJN.S55066> [PubMed]
- Mironov AN (2012) Guidelines for pre-clinical trials of medicines. Moscow: Grif i Co, 944 pp. [in Russian]
- Ovcharenko SI, Glukhareva NS (2009) Efficacy and safety of using Erespal (fenspiride hydrochloride) in the treatment of acute respiratory infections in children in the first months of life. *Pediatrics [Pediatria]* 3: 101–103. [in Russian]
- Poryadin GV (2014) Pathophysiology: lectures: tutorial. GEOTAR-Media, Moscow, 592 pp. [in Russian]
- Qadir MI, Parveen A, Abbas K, Ali M (2016) Analgesic, anti-inflammatory and anti-pyretic activities of *Thymus linearis*. *Pakistan Journal of Pharmaceutical Sciences* 29(2): 591–594. [PubMed]
- Serebryannikov SN, Seminsky IZh (2014) Pathophysiology of the inflammatory process: tutorial. Irkutsk: Irkutsk State Medical University, 82 pp. [in Russian]
- Sokolov AS (2003) Erespal (fenspiride) in the treatment of diseases of the bronchopulmonary system and ENT organs. *Pulmonology [Pul'monologiya]* 13(5): 122–127. [in Russian]
- Sokolov SYa (2000) Phytotherapy and phytopharmacology. Guidance for doctors. Moscow: Medical information Agency, 976 pp. [in Russian]
- Tatochenko VK (2007) Differential diagnosis and treatment of cough in children. *Children's doctor [Detskii Doktor]* 1: 4–7. [in Russian]
- Tolstikov GA, Baltina LA, Shul'ts EE, Pokrovskii AG (1997) Glycyrrhizic acid. *Russian Journal of Bioorganic Chemistry [Bioorganicheskaya Khimiya]* 23(9): 691–709. [in Russian]

Author Contributions

- **Pavel D. Kolesnichenko**, PhD in Medicine, Associate Professor, e-mail: farpavel@yandex.ru. **ORCID ID: 0000-0002-2434-994X**. The author carried out experimental work, statistical processing and evaluation of anti-inflammatory activity of the drugs in the experiment.
- **Anna A. Peresyphkina**, PhD in Biology, Associate Professor, e-mail: anny_87@mail.ru. **ORCID ID: 0000-0003-2829-9860**. The author carried out evaluation of anti-inflammatory activity of the drugs in the experiment, as well as conducted analysis and interpreted the results.
- **Artem A. Poromov**, PhD in Biology, senior researcher, e-mail: poromov@instmech.ru. **ORCID ID: 0000-0002-2004-3935**. The author carried out experimental, participated in planning the experiments and discussing the results.
- **Elena N. Kareva**, Doctor of Medical Sciences, Professor, e-mail: elenakareva@mail.ru. **ORCID ID: 0000-0002-9441-3468**. The author participated in the discussion of the results.
- **Alexey V. Tverskoi**, PhD in Medicine, Associate Professor, e-mail: tverskoy@yandex.ru. The author interpreted the histological data.
- **Alexey N. Demidenko**, PhD in Medicine, Senior Lecturer, e-mail: demidonkolor@yandex.ru. The author carried out the biochemical analysis of experimental animals blood plasma.