



# Effect of complex therapy with Cortexin on the state of the body's regulatory systems in patients with rosacea

Alexandra A. Bobrakova<sup>1</sup>

<sup>1</sup> State Budgetary Institution of Healthcare "Oryol Regional Skin and Venereologic Clinic" 68 Pushkina St., Oryol 302030, Russia

Corresponding author: Alexandra A. Bobrakova ([novikovalexandra2012@mail.ru](mailto:novikovalexandra2012@mail.ru))

**Academic editor:** T. Pokrovskaya ♦ **Received** 28 November 2019 ♦ **Accepted** 19 December 2019 ♦ **Published** 5 March 2020

**Citation:** Bobrakova AA (2020) Effect of complex therapy with Cortexin on the state of the body's regulatory systems in patients with rosacea. *Research Results in Pharmacology* 6(1): 21–27. <https://doi.org/10.3897/rrpharmacology.6.50533>

## Abstract

**Introduction:** For treating patients with rosacea, it is important to study the effectiveness of drugs with both neuro-modulating activity and immunomodulatory properties. The aim of the study is to examine the nature of biochemical parameters, the state of the blood antioxidant system, and the state of the immune system in patients with rosacea before and after a traditional treatment and the treatment using Cortexin.

**Materials and methods:** 216 people participated in the study. All the patients received a traditional therapy. The patients in the study group additionally received Cortexin at a dose of 10 mg intramuscularly № 10. The clinical examination of the patients included a thorough collection of complaints, life histories, medical histories, and physical examination. The state of the skin, the hepatobiliary system, the blood antioxidant system, the immune and the endocrine systems were studied in detail.

**Results and discussion:** The therapy using Cortexin made it possible to achieve a better clinical effect in terms of dermatological status. Thanks to the innovative treatment, 40% of the patients got rid of the clinical manifestations of the disease, and none of patients was reported to have no clinical effect. The patients with rosacea had disorders in the hepatobiliary system, an imbalance in the lipid peroxidation system and in the blood antioxidant system, as well as hyperactivation of the cellular and humoral parts of the immune system. The therapy with Cortexin did not have a significant advantage over the traditional treatment in the processes of normalization of the hepatobiliary system and the antioxidant system of the blood. However, Cortexin, being a complex of natural low-molecular-weight peptides, had a corrective effect on the cellular and humoral parts of the immune system. Unlike the traditional treatment, which maintained elevated levels of helper T-lymphocytes, lymphocytic index and interleukin 12, against the background of a slightly reduced level of T-lymphocyte suppressors.

**Conclusion:** As a result of the Cortexin use in complex therapy, the patients with rosacea had a faster normalization of their dermatological and immune statuses.

## Keywords

rosacea, Cortexin.

## Introduction

Rosacea is a common inflammatory dermatosis that affects the skin of the face (Marson and Baldwin 2019). According to Russian authors, rosacea has the highest proportion (36%) in the structure of acne-like dermatoses (Yutskovskaya et al. 2010). In the Russian Federation, rosacea accounts for about 5% of all dermatological diagnoses. However, according to Russian cosmetologists, the real figure reaches 20.6% (Tan et al. 2016). Despite the large number of scientific studies on the problem of rosacea, there is still no clear concept of the etiology and pathogenesis of this disease, and the mechanisms of its formation have not been fully studied.

Many authors associate the occurrence of rosacea with disorders in the dermal matrix (Steinhoff et al. 2013), with the action of microorganisms, the genetic predisposition (Aldrich et al. 2015; Chang et al. 2015), with disorders of the gastrointestinal tract and the hepatobiliary system (Parish and Witkowski 1995; Gravina et al. 2015; Egeberg et al. 2017; Yang 2018), the endocrine (Spoendlin et al. 2013a) and nervous systems (Jafferany 2007; Spoendlin et al. 2013b; Egeberg et al. 2016a), with changes in the immune status (Schmidt et al. 1983; Yamasaki and Gallo 2011; Egeberg et al. 2016b), as well as with the impact of the environmental factors.

One of the key links in the mechanisms of the rosacea development is the development of the local angioneurosis (Mimov 2013), associated with the disruption of the peripheral nerve endings. Involvement of the nervous system in the pathogenesis does not end with the damage to these segments. A cosmetic defect in the form of dry and itchy skin is the most significant permanent irritation trigger for the nerve endings, involving the brain in the chain of pathogenesis by forming an imbalance in brain functioning and involving the entire body in the pathological process, in particular the human adaptation system.

In this regard, it is important to study the effectiveness of the drugs with both neuromodulating activity and immunomodulatory properties (Irwin 2008; Schwab et al. 2011), affecting the body's regulatory systems in patients with rosacea.

Cortexin is a neuropeptide drug, being a complex of low-molecular-weight peptides isolated from the cerebral cortex of cattle and pigs. A set of Cortexin components provides neurotropic, cytoprotective, immunomodulatory, membrane-stabilizing, and antioxidant effects (Coulter et al. 1993; Khorshev et al. 2002; Studenikin 2006). Cortexin is widely used in clinical practice as a cerebroprotective, nootropic, and neurometabolic agent.

However, in the literature there are indications of the immunomodulatory effect of Cortexin in the treatment of the neurological diseases, its corrective effect on the cellular and humoral links of the immune system (Khorshev et al. 2008). The use of Cortexin in the treatment of organic mental disorders was accompanied by normalization of immune parameters (an increase in the number of T and B lymphocytes, the restoration of the number

and ratio of CD4+ and CD8+ cells in blood without any pronounced changes in the concentration of immunoglobulins A, M, and G, as well as the content of circulating immune complexes) (Khorshev et al. 2008). In (Khorshev et al. 2008), Cortexin is considered as a corrector of the neuroimmune component of the pathological process. This observation is important for the treatment of rosacea, since the immunological aspects of rosacea pathogenesis are much discussed in the literature. And the presence of the cytoprotective, membrane-stabilizing and antioxidant effects increases the relevance of considering neuropeptide drug Cortexin as an adjunct in the treatment of rosacea.

The aim of the study is to study the nature of biochemical parameters, the state of the lipid peroxidation system, the blood antioxidant system, and the immune system in the patients with rosacea before and after the traditional treatment and a treatment using Cortexin.

## Materials and methods

The study was conducted on the basis of the state budgetary healthcare institution "Oryol Regional Skin and Venerologic Clinic" in 2014–2017. The work was organized and conducted in accordance with the legal acts and guidelines governing clinical trials in the Russian Federation. Before the start of the study, all the patients were informed of the goals and objectives of the study, each of them gave written informed consent to participate in it and to have the results of their diagnosis and treatment published, while treating the information about the patients as confidential. The study involved 216 people, of both sexes, aged from 20 to 60 years, who received an outpatient treatment. All the patients were divided into 2 groups: a study group with an innovative treatment consisted of 109 people, and the control group – 107 people.

The general inclusion criteria for the study:

- informed consent of a patient to participate in the study and follow the doctor's instructions;
- having a clinically confirmed diagnosis of rosacea in the acute stage;
- age over 18 years.

The exclusion criteria for the study:

- not meeting the inclusion criteria for the study;
- having physiological conditions (pregnancy, lactation);
- neoplastic process;
- individual intolerance to the drugs of the treatment regimen.

A compulsory criterion for inclusion in the group of the innovative treatment was the prescription of Cortexin by the neurologist for medical reasons (consequences of traumatic brain injury, encephalopathy of various origins,

cognitive disorders (memory and thought disorders), epilepsy, or asthenic conditions).

All the respondents received a traditional therapy in accordance with the Federal Clinical Guidelines for the Management of Rosacea Patients by the Russian Society of Dermatologists and Cosmetologists (2010). The patients of the innovative treatment group additionally received Cortexin at a dose of 10 mg intramuscularly № 10.

The clinical examination of patients included a thorough collection of complaints, life histories, medical histories, and a physical examination. The states of the skin, the hepatobiliary system, the lipid peroxidation system, the blood antioxidant system, the immune and endocrine systems were studied in detail. For that, in addition to the complaints about the skin condition, the following laboratory indicators were evaluated: biochemical blood analysis (total cholesterol, total bilirubin, alanine transaminase (ALT), aspartate aminotransferase (AST), gamma-glutamyltranspeptidase (GGT), thymol sample the level of pro-oxidants and antioxidants in blood systems (catalase, superoxide dismutase (SOD), total antioxidant activity of blood plasma (TAA), malone dialdehyde (MDA) and acetyl hydroperoxide (AHP), performance indicators of the cellular and humoral links of the immune system, of the monocytic-macrophage link and of the inflammatory mediators. The assessment and determination of the severity of the dermatological status were based on the standard classification of rosacea (Wilkin et al. 2002) and the Rosacea Diagnostic Evaluation Score (RDES) (Adaskevich 2004). Examinations were performed before and after the treatment according to standard regimens and using Cortexin.

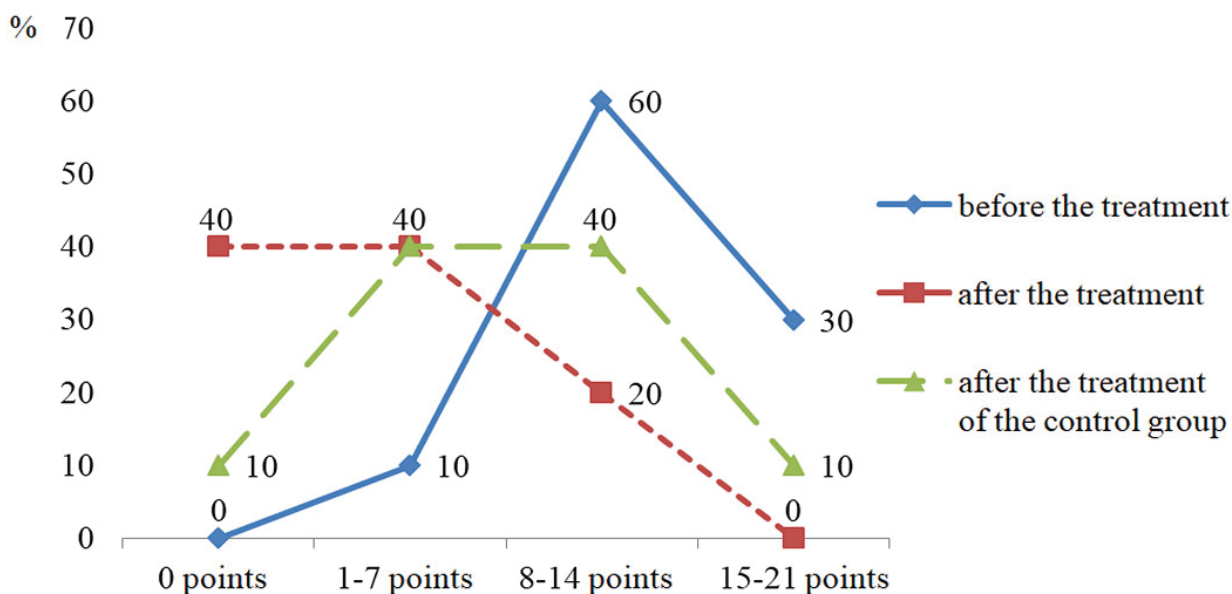
The obtained data was processed using descriptive statistics of the Microsoft Excel 2007 data package.

## Results and discussion

In order to evaluate the impact of the internal and external factors on the pathological process, the anamnestic data of patients from both study groups were analyzed. The duration of the disease in the patients was on average from 3 to 18 years. The majority of the patients, 57.8%, reported the duration of the pathological process to have lasted from 6 to 11 years. The duration of the disease from 1 to 3 years was reported by 9.3% of the patients. In this group of patients, the pathological process proceeded in a lighter form, without involving new skin areas. A third – 32.9%, had a history of the disease from 12 to 20 years. They were mostly middle-aged and elderly patients. During these age periods, there was a significant decrease in the recovery functions of the body, which resulted in a longer process, a poor response to the therapy, and a decrease in the duration of remission periods. A large group of the surveyed, 43%, reported exacerbations once a year, mainly in spring and summer periods, which can be accounted for by an increased insolation (Jansen 2011). Another 26% of the patients recorded the exacerbations twice a year, 19% – less than once a year, and 12% – 3 or more times a year.

The analysis of the clinical picture revealed that before the treatment, all the patients reported dry skin. The majority, 80%, complained of itching of various intensity. Telangiectasias were visualized in 90% of the patients. Erythema was observed in 35% of the patients, papular exanthemums – in 16%. Facial swelling was detected in 8.8%.

During the study, the Rosacea Diagnostic Evaluation Score was applied before and after the treatment for the purpose of statistical evaluation of the clinical manifestations of rosacea (Fig. 1).



**Figure 1.** Dynamics of clinical manifestations of rosacea against the background of the traditional and investigational therapy with Cortexin.

Most cases of rosacea were of Stage II and Stage III. The analysis of the indicators of the Rosacea Diagnostic Evaluation Score revealed a significant decrease of negative signs of rosacea in the patients who had received the complex therapy using Cortexin in contrast to the patients who had received the traditional treatment. Thus, the therapy using Cortexin made it possible to get rid of the clinical manifestations of the disease in 40% of the patients, and none of the patients in this group lacked a clinical effect.

The next stage of the study was an analysis of comorbidities in the rosacea patients (Fig. 2). Out of the examined patients, 65.1% suffered from a concomitant pathology. Among the most common pathologies, there were diseases of the gastrointestinal tract and nervous system.

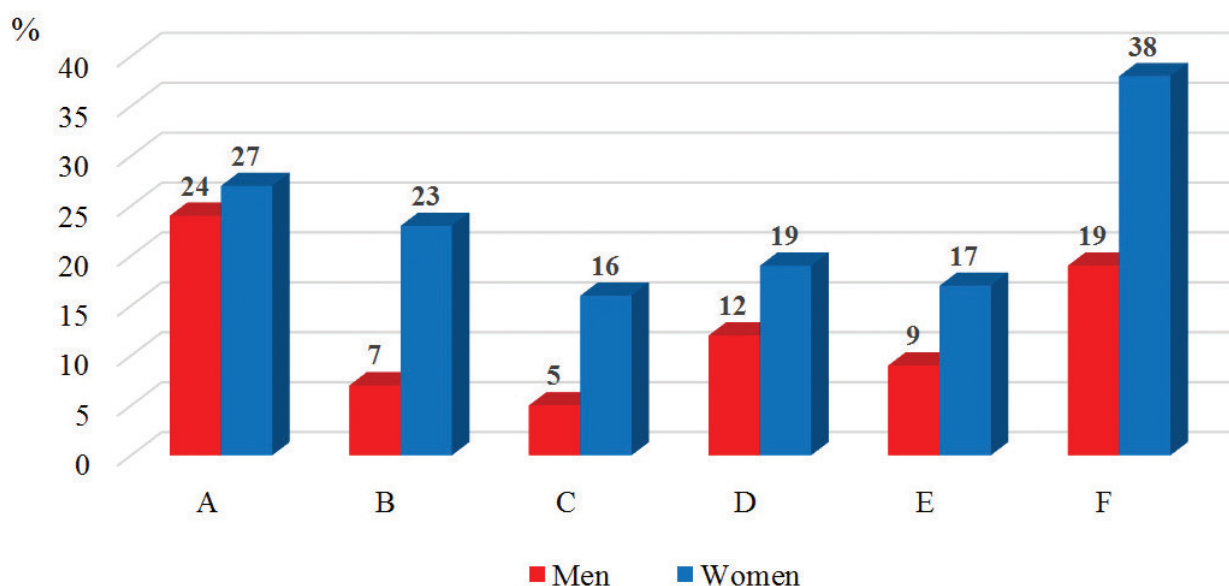
Rosacea, being a multifactorial disease, implies the presence of the predisposing and provoking changes in the functioning of various organs and systems of the body. Assuming a significant role of the digestive system and, in particular, the hepatobiliary system in the pathogenesis of disease, the key indicators of the liver were examined (Table 1).

Before the treatment, the indicators in both groups did not differ significantly. There was a slight increase in cholesterol, bilirubin, transaminases, and thymol sam-

ples, which indicated disorders of the hepatobiliary system in the rosacea patients. During the therapy in both groups, there was a tendency to normalize biochemical parameters, with the cholesterol level and the values of the thymol sample in the patients of the study group of innovative treatment getting significantly lower than those in the patients of the control group. This indicates the process of normalization of the structure and the dynamics of the inflammation processes.

The lipid peroxidation system (LPS) and the blood antioxidant system (BAS) play an essential role in organizing the proper functioning of the body. Thus, a disturbance of balance of the pro- and antioxidant systems of blood is a provoking factor for activating the pathogenesis of many chronic conditions, including rosacea.

Observing the initial parameters of the lipid peroxidation products and the oxidative modification of plasma proteins, superoxide dismutase, and total antioxidant activity of plasma, an imbalance in the LPS-BAS system was found in rosacea patients (Table 2). The LPS-BAS system reacted to the inflammatory process by increasing shifts in MDA and AHP indicators, which showed activation of the neutrophilic link in the peripheral blood. The MDA index in the rosacea patients was almost 2 times higher than that of the healthy donors. The level of AHP was sig-



**Figure 2.** Concomitant somatic pathology in rosacea patients. Note: **A** – diseases of the gastrointestinal tract; **B** – neurological pathology; **C** – endocrine dysfunction; **D** – diseases of the cardiovascular system; **E** – combined pathology; **F** – no pathology.

**Table 1.** Dynamic Changes in Biochemical Parameters in Patients with Rosacea During the Treatment.

Indicants	Study group		Control group	
	Before treatment	After treatment	Before treatment	After treatment
Cholesterol, mm /L	5.75±0.28	3.52±0.09* #	6.09±0.26	4.22±0.11*
Bilirubin, mmol/L	20.66±0.96	11.06±1.1*	19.96±0.96	12.08±1.15*
ALT, IU/L	38.34±1.64	20.9±1.95*	37.36±1.64	22.7±1.84*
AST, IU/L	37.22±1.62	20.65±0.97*	37.12±1.62	22.04±0.88*
GGT, IU	33.03±0.68	19.95±0.93*	34.91±0.68	19.37±0.96*
Thymol turbidity test, IU	6.55±0.55	1.8±0.07* #	5.95±0.55	2.0±0.10*

**Note:** \* –  $p < 0.05$  – compared to the pre-treatment group; # –  $p < 0.05$  – compared to the control group.

**Table 2.** Dynamic Changes in Indicators of the LPS-BAS System in Patients with Rosacea During Treatment.

Indicants	Study group		Control group	
	Before treatment	After treatment	Before treatment	After treatment
Catalase, mcg/ml	8.9±1.07	18.86±1.3*	9.2±1.16	17.54±1.6*
TAA, %	40.26±2.4	50.07±1.7*	44.29±2.4	52.01±1.5*
SOD, IU/ml	9.98±0.61	10.3±1.3	10.08±0.61	11.1±1.21
MDA, uIU/ml	5.75±0.8	2.83±0.3*	5.95±0.89	2.96±0.6*
AHP, IU	0.88±0.04	0.18±0.02*	0.89±0.05	0.21±0.04*

Note: \* – p<0.05 – compared to the group before treatment.

**Table 3.** Dynamic Changes in Immune System Parameters in Patients with Rosacea During Treatment.

Indicants	Study group		Control group		Control values (norm)
	Before treatment	After treatment	Before treatment	After treatment	
CD4+, %	51.0±0.5°	45.0±0.3*	49.0±0.1°	46.0±0.4*°	45.0±0.2
CD8+, %	17.0±0.3°	21.0±0.4*#	17.2±0.6°	19.0±0.3*°	21.0±0.2
CD4+/CD8+	2.8±0.1°	2.2±0.3*#	2.8±0.2°	2.4±0.2*°	2.1±0.1
CD16+, %	11.9±0.9°	13.2±0.6*#	10.2±0.1°	12.7±0.2*°	14.3±0.7
CD22+, %	12.7±0.4°	14.1±0.9*	11.8±0.2°	14.4±0.6*	14.3±0.1
IgG, g/L	18.5±1.1°	14.0±0.1*	18.5±0.8°	13.7±0.9*	13.5±0.3
IgA, g/L	3.9±0.9°	2.2±0.3*	3.2±1.0°	2.0±0.2*	2.0±0.6
IgM, g/L	1.7±0.4°	1.2±0.3*	1.5±0.5°	1.2±0.4*	1.1±0.3
HCT test, %	27.6±2.0°	23.6±1.2*#	27.6±7.3°	27.8±1.1°	22.5±1.6
IL10, %	18.5±1.3°	14.5±2.1*	18.4±2.2°	14.9±3.2*	12.3±1.9
IL12, %	41.8±6.1°	36.6±5.0*	41.6±4.9°	38.0±5.0*°	32.3±2.3

Note: \* – p<0.05 - compared to the pre-treatment group; # – p<0.05 - compared to the control group; ° – p<0.05 - compared to the control values.

nificantly (3 times) higher in all forms of rosacea than in the group of the healthy individuals.

During the treatment, there was a marked tendency to normalize the functioning of the LPS-BAS system in both groups. This was expressed in an increase in the activity of enzymes of the antioxidant system (catalase and plasma TAA), as well as a decrease in the content of lipid peroxidation products (MDA, AHP). There were no significant differences in the indicators of the LPS-BAS system in the study and control groups. The comparison of the data showed a decrease in the activity of the inflammatory process against the background of the therapy, by normalizing the indicators of the LPS-BAS system.

The state of the immune cell link was evaluated before treatment by the levels of helper T-lymphocytes, suppressor T-lymphocytes, lymphocytic index, killer T-lymphocytes, and B-lymphocytes (Table 3).

Before treatment, the level of the immunologic profile in the patients with rosacea showed a significant increase in the immune-regulatory index – the ratio of CD4+/CD8+ by increasing the level of T-helpers (CD4+) and reduced T-suppressor (CD8+), which reflects the intensity of immune responses and suggests the hyperactivity of the immune system. There was also a decrease in the level of natural killer cells and B-lymphocytes, and an increase in the phagocytic activity of neutrophils (NBT test).

In the process of evaluating the humoral immunity indicators (Table 3), the majority of patients showed an increase in the production of the main classes of immunoglobulins – IgG, IgA, IgM in blood serum, as well as an increase in the level of anti-inflammatory cytokines IL-10 and IL-12.

After the therapy, the normalization of immune system parameters was recorded in the patients who had taken

Cortexin. In the patients of the control group, the levels of helper T-lymphocytes, lymphocytic index, and interleukin 12 remained elevated, against the background of slightly reduced levels of suppressor T-lymphocytes.

The neurotrophic drug Cortexin is a lyophilizer of the cerebral cortex of calves. It consists of neuropeptides, amino acids, and trace elements. All these components of Cortexin determine the spectrum of its indications for specific correction of molecular and cellular processes at various stages of the pathological process. The therapy using Cortexin significantly optimized the treatment prognosis and made it possible to achieve the best therapeutic result in the treatment of patients with rosacea.

## Conclusion

1. Therapy using Cortexin made it possible to achieve a better clinical effect in terms of dermatological status, compared with the traditional therapy. The innovative treatment helped 40% of the patients get rid of the clinical manifestations of the disease, and none of the patients in this group lacked a clinical effect.
2. The therapy with Cortexin does not have a significant advantage over the traditional treatment in the processes of normalization of the hepatobiliary system and the blood LPS-BAS.
3. Cortexin, being a complex of natural low-molecular-weight peptides, has a corrective effect on the cellular and humoral parts of the immune system. The therapy with Cortexin resulted in normalization of immune system parameters in the patients with rosacea. In contrast to the traditional treatment,

which maintained elevated levels of helper T-lymphocytes, lymphocytic index and interleukin 12, against the background of slightly reduced levels of T-lymphocyte suppressors.

## Conflict of interests

The author declares no conflict of interest.

## References

- Adaskevich VP (2004) Diagnostic Indices in Dermatology. Medical Book [Meditsinskaya Kniga], Moscow, 165 pp. [in Russian]
- Aldrich N, Gerstenblith M, Fu P, Tuttle MS, Varma P, Gotow E, Cooper KD, Mann M, Popkin DL (2015) Genetic vs environmental factors that correlate with rosacea: A cohort-based survey of twins. *JAMA Dermatology* 151(11): 1213–1219. <https://doi.org/10.1001/jamadermatol.2015.2230> [PubMed]
- Chang AL, Raber I, Xu J, Li R, Spitalo R, Chen J, Kiefer AK, Tian C, Eriksson NK, Hinds DA, Tung JY (2015) Assessment of the genetic basis of rosacea by genome-wide association study. *The Journal of Investigative Dermatology* 135(6): 1548–1555. <https://doi.org/10.1038/jid.2015.53> [PubMed] [PMC]
- Coulter II PM, Bautista EA, Margulies JE, Watson JB (1993) Identification of cortexin: a novel, neuron-specific, 82-residue membrane protein enriched in rodent cerebral cortex. *Journal of Neurochemistry* 61(2): 756–759. <https://doi.org/10.1111/j.1471-4159.1993.tb02183.x> [PubMed]
- Egeberg A, Hansen PR, Gislason GH, Thyssen JP (2016a) Clustering of autoimmune diseases in patients with rosacea. *Journal of the American Academy of Dermatology* 74(4): 667–672. <https://doi.org/10.1016/j.jaad.2015.11.004> [PubMed]
- Egeberg A, Hansen PR, Gislason GH, Thyssen JP (2016b) Patients with rosacea have increased risk of depression and anxiety disorders: A Danish nationwide cohort study. *Dermatology* 232(2): 208–213. <https://doi.org/10.1159/000444082> [PubMed]
- Egeberg A, Weinstock LB, Thyssen EP, Gislason GH, Thyssen JP (2017) Rosacea and gastrointestinal disorders: a population-based cohort study. *The British Journal of Dermatology* 176(1): 100–106. <https://doi.org/10.1111/bjd.14930> [PubMed]
- Gravina A, Federico A, Ruocco E, Lo Schiavo A, Masarone M, Tuccillo C, Peccerillo F, Miranda A, Romano L, de Sio C, Persico M, Ruocco V, Riegler G, Loguercio C, Romano M (2015) Helicobacter pylori infection but not small intestinal bacterial overgrowth may play a pathogenic role in rosacea. *United European Gastroenterology Journal* 3(1): 17–24. <https://doi.org/10.1177/2050640614559262> [PubMed] [PMC]
- Horshev SK, Yakov YuI, Bessmeltsev SS (2002) Cortexin as a corrector of the neuroimmune component of epileptogenesis. *Materials of The XI All-Russian Conference 1*: 301–302. [in Russian]
- Irwin MR (2008) Human psychoneuroimmunology: 20 years of discovery. *Brain, Behavior, and Immunity* 22(2): 129–139. <https://doi.org/10.1016/j.bbi.2007.07.013> [PubMed]
- Jafferany M (2007) Psychodermatology: A guide to understanding common psychocutaneous disorders. *Primary Care Companion to the Journal of Clinical Psychiatry* 9(3): 203–213. <https://doi.org/10.4088/PCC.v09n0306> [PubMed] [PMC]
- Jansen T (2011) Clinical presentations and classification of rosacea. In: *Annales de Dermatologie et de Vénérologie* 138 (Suppl 3): S192-S200. [https://doi.org/10.1016/S0151-9638\(11\)70089-8](https://doi.org/10.1016/S0151-9638(11)70089-8) [PubMed]
- Khorshev SK, Korsakova EA, Stolyarov ID, PolyakovYuI, Mashukova VE, Kolyada AA (2008) Prophylactic treatment of epilepsy: possibilities of Cortexine (neuroimmunophysiological and biochemical investigation). *Neuroimmunology [Neuroimmunologiya]* 6(1): 22–26. [in Russian]
- Marson JW, Baldwin HE (2019) Rosacea: a wholistic review and update from pathogenesis to diagnosis and therapy. *International Journal of Dermatology* <https://doi.org/10.1111/ijd.14757> [PubMed]
- Mimov AV (2013) The combined use of pulsed laser radiation and ultrasound in the treatment of rosacea patients. *Journal of New Medical Technologies [Vestnik Novykh Meditsinskikh Tekhnologij]* 1: 1–215. [in Russian]
- Parish LC, Witkowski JA (1995) Acne rosacea and Helicobacter pylori betrothed. *International Journal of Dermatology* 34(4): 236–237. <https://doi.org/10.1111/j.1365-4362.1995.tb01586.x> [PubMed]
- Schmidt JB, Raff M, Spona J (1983) Do sexual steroids contribute to the pathomechanism of rosacea? A study of estrogen and androgen receptors in acne rosacea. *Acta Dermato-Venereologica* 63(1): 64–66. [PubMed]
- Schwab VD, Sulk M, Seeliger S, Nowak P, Aubert J, Mess C, Rivier M, Carlván I, Rossio P, Metzke D, Buddenkotte J, Cevikbas F, Voegel JJ, Steinhoff M (2011) Neurovascular and neuroimmune aspects in the pathophysiology of rosacea. *The Journal of Investigative Dermatology. Symposium Proceedings* 15(1): 53–62. <https://doi.org/10.1038/jidsymp.2011.6> [PubMed] [PMC]
- Spöndlin J, Voegel JJ, Jick SS, Meier CR (2013a) Migraine, triptans, and the risk of developing rosacea: a population-based study within the United Kingdom. *Journal of the American Academy of Dermatology* 69(3): 399–406. <https://doi.org/10.1016/j.jaad.2013.03.027> [PubMed]
- Spöndlin J, Voegel JJ, Jick SS, Meier CR (2013b) Risk of rosacea in patients with diabetes using insulin or oral antidiabetic drugs. *The Journal of Investigative Dermatology* 133(12): 2790–2793. <https://doi.org/10.1038/jid.2013.225> [PubMed]
- Steinhoff M, Schaubert J, Leyden JJ (2013) New insights into rosacea pathophysiology: a review of recent findings. *Journal of the American Academy of Dermatology* 69(6 Suppl 1): S15-S26. <https://doi.org/10.1016/j.jaad.2013.04.045> [PubMed]
- Studenikin VM (2006) The use of the drug cortexin in neuropediatrics. *Medical Messenger [Meditsinskii Vestnik]* 37(380): 14. [in Russian]
- Tan J, Schofer H, Araviiskaia E, Audibert F, Kerrouche N, Berg M, RISE study group (2016) Prevalence of rosacea in the general population of Germany and Russia. The RISE study. *Journal of the European Academy of Dermatology and Venereology: JEADV* 30(3): 428–434. <https://doi.org/10.1111/jdv.13556> [PubMed] [PMC]
- Wilkin J, Dahl M, Detmar M, Drake L, Feinstein A, Odom R, Powell F (2002) Standard classification of rosacea: Report of the National Rosacea Society Expert Committee on the Classification and Staging of Rosacea. *Journal of the American Academy of Dermatology* 46(4): 384–387. <https://doi.org/10.1067/mjd.2002.120625> [PubMed]
- Yamasaki K, Gallo RL (2011) Rosacea as a disease of cathelicidins and skin innate immunity. *The Journal of Investigative Dermatology*

- gy. Symposium Proceedings 15(1): 12–15. <https://doi.org/10.1038/jidsymp.2011.4> [PubMed]
- Yang X (2018) Relationship between *Helicobacter pylori* and Rosacea: review and discussion. *BMC Infectious Diseases* 18(1): 1–318. <https://doi.org/10.1186/s12879-018-3232-4> [PubMed] [PMC]
  - Yutskovskaya YaA, Kusaya NV, Klyuchnik SB (2010) The rationale for pathogenetic therapy for acne-like dermatoses complicated by tick-borne invasion *Demodex folliculorum*. *Russian Journal of Clinical Dermatology and Venereology [Klinicheskaya Dermatologiya i Venerologiya]* 3: 60–63. [in Russian]

## Author contributions

- **Alexandra A. Bobrakova**, dermatovenerologist, Head of the State Budgetary Institution of Healthcare "Oryol Regional Skin and Venereologic Clinic", e-mail: [novikovalexandra2012@mail.ru](mailto:novikovalexandra2012@mail.ru) The author defined the purpose and objectives of the study, developed its design, analyzed the current scientific literature on the topic of the study, collected the material, analyzed and interpreted the results of the study.